University Journal of Surgery and Surgical Specialities

ISSN 2455-2860 2020, Vol. 6(1)

# A rare case of Superior Orbital Fissure Syndrome secondary to metastatic Prostatic Carcinoma

**TUSHAR GROVER**
Department of Ophthalmology, ARAVIND EYE HOSPITAL & PG INSTITUTE OF OPHTHAMOLOGY

**Abstract :** Superior Orbital Fissure syndrome is an infrequently described symptom complex presenting as ptosis of the upper eye lid, proptosis of the globe, ophthalmoplegia, fixation and dilatation of the pupil, and anaesthesia of the upper eyelid and forehead. We present a case of a 56 year old male presenting with recent onset dropping of the left upper eye lid. On eliciting detailed history, the patient revealed to be a known case of Prostatic Carcinoma on treatment at a cancer care centre. On clinical examination, the left eye showed exotropia and limitation of all the extraocular movements, suggesting an involvement of 3rd and 6th Cranial nerves. This indicated the likely site of lesion at the Superior Orbital Fissure. Imaging confirmed the above and the Superior Orbital Fissure syndrome was seen to be secondary to extensive intracranial metastasis from prostatic carcinoma. Extensive skeletal metastasis were also seen to be involving the chest, abdomen and pelvic bones. The patient was subsequently referred to a tertiary cancer care centre for treatment. Prostatic carcinoma is extremely rarely seen to present with cranial nerve palsies and no other case of Prostatic Carcinoma presenting as Superior Orbital Fissure was found in literature. This case highlights the importance of a thorough history and evaluation of neurological symptoms in cases presenting with cranial nerve palsies. Also, investigations like contrast CT and PSA levels can help rule out sinister underlying causes of these symptoms

**Keyword :**Superior Orbital Fissure Syndrome,Prostatic Carcinoma, Multiple Cranial Nerve Palsies, Third nerve palsy, Sixth nerve palsy

## CASE REPORT

A 56 year old male presented to us with the complaint of drooping of the left upper eye lid for the last 2 days. There was no associated double vision, pain or any complaint of defective vision. The patient as a non smoker, non alcoholic. On eliciting further history, the patient revealed to be a known case of prostate cancer with bone metastasis on treatment at a cancer institute in his city of residence. There was no history of headache, vomiting, seizures or giddiness, no history of back pain or joint paints. He had no other relevant systemic history like diabetes or systemic hypertension. Visual acuity was 6/6 in the Right eye and 6/6P improving to 6/6 with -0.5 cylinder at 600 in the left eye. Intraocular Pressure was 11 mm Hg in the right eye and 16 mm Hg in the left eye

**Near complete ptosis in the left eye**

On Ocular examination, the Right eye had a normal anterior segment. In the left eye, a near complete ptosis was present. Exotropia of the left eye was seen. The pupil was 4 mm in diameter and showed a sluggish reaction in the left eye. Fundus showed normal disc and vessels and a bright foveal reflex indicating a healthy macula in both the eyes.

**Extrocular movement limitation**

The left eye showed limitation of all extraocular movements (marked limitation of elevation, depression, adduction and mild limitation of abduction). Extraocular movements in the right eye were found to be normal Corneal sensation was normal in both the eyes.Colour vision assessment by Ishihara's Pseudoisochromatic chart was normal in both the eyes. Bjerrum's Central field evaluation was found to be normal in both the eyes. Hess and diplopia charting was done which were suggestive of an involvement of the 3rd and 6th cranial nerves.

The above clinical findings suggested the involvement of multiple cranial nerves, with the most likely site of lesion at the Superior Orbital Fissure. The histopathological examination of the primary tumour showed a prostatic adenocarcinoma, pT3N1M1 stage with a Gleason's score of 9(5 + 4). Perineural invasion was seen. The margins were free of tumour

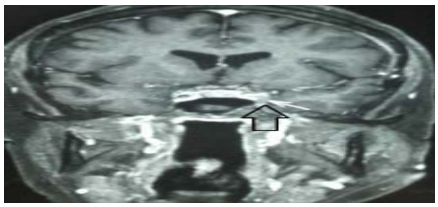

**MRI Brain with intracranial metastasis involving the 3rd, 4th and 6th cranial nerves at the Superior Orbital Fissure(Black arrow)**

An MRI Brain was advised to confirm the same and identify the nature of the lesion. MRI – Brain showed evidence of extensive skeletal metastasis replacing most of the axial and appendicular skeleton including skull vault, skull base, clivus, sternum and scapula with soft tissue mass formation encroaching into Dorello's canal, Meckel's cave and para cavernous region (Left > Right) with engulfement of 3rd, 4th and 6th cranial nerves and V1 and V on left side. It also showed evidence of leptomeningeal secondaries also noticed with trace of extra conal deposits seen adjacent to LR muscle on left side Multislice CT of skull/ chest/abdomen/pelvic bones was done to rule out secondaries elsewhere in the body which showed evidence of large expansile and destructive lesions involving left iliac bone and most of the ribs with invasion of iliacus muscle ( anteriorly) and gluteus minimus (posteriorly)

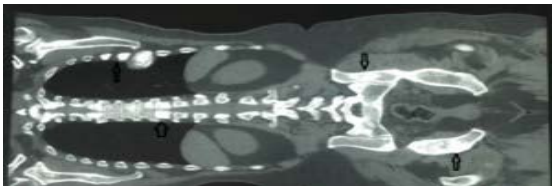

**Extensive skeletal metastasis to the chest,abdomen and pelvic bones(arrows)**

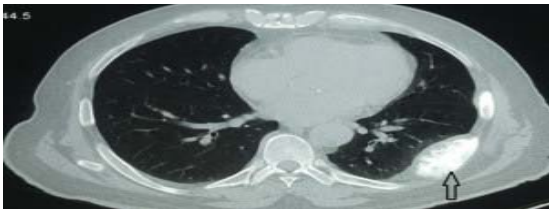

**Metastasis involving the ribs(arrow)**

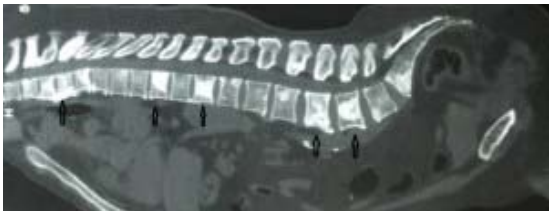

**Metastasis to the vertebrae(arrows)**

Based on the above findings, the patient was referred to a tertiary cancer care centre. Subsequently the patient was lost for follow up and could not be contacted

**DISCUSSION**

Superior Orbital Fissure syndrome, first described by Hirschfield in 18581, is an infrequently described and reported symptom complex. SOFS consists of the following signs: ptosis of the upper eyelid, proptosis of the globe, ophthalmoplegia, fixation and dilatation of the pupil, and anesthesia of the upper eyelid and forehead2. The superior orbital fissure serves as a pathway allowing communication between the orbit and the middle cranial fossa.4 The fissure is reported to be 3 X 22 mm2 and transmits the oculomotor, trochlear, and abducens nerves (cranial nerves III, IV, and VI), as well as the first three branches of the trigeminal nerve: the frontal, lacrimal, and nasociliary nerves.4 Also contained in the fissure is the inferior and superior ophthalmic veins and the sympathetic filaments from the cavernous plexus.4 Numerous etiologies of the syndrome have been reported in the literature.

These include syphilis, craniofacial fractures, hematoma of the cavernous sinus or retrobulbar space, infection, neoplasm, aneurysm of the internal carotid artery or arteriovenous fistulae, or idiopathic etiologies.1–9 Regardless of the etiology, the clinical symptoms are primarily the result of inflammation and compression of adjacent nervous tissue.6 Lid ptosis is caused by either the involvement of the sympathetic fibers arising from the cavernous sinus, resulting in loss of tone of Muller muscles, or the involvement of the somatic efferent fibers that course along the superior branch of the oculomotor nerve, resulting in loss of tone of the levator palpebrae superioris muscle.4,6 The ophthalmoplegia is secondary o impairment of cranial nerves III, IV, and VI.1–9 Disturbance of the lacrimal and frontal nerves leads to anesthesia of the forehead and upper eyelid.4,6 In SOFS secondary to facial trauma, a complete or partial recovery can be expected without any intervention aimed at the fissure itself as long as the nerves are intact7 Varying doses of systemic corticosteroids have been advocated.4, 5, 8, 9 The benefits of steroids appear to be from the antioxidant mechanism and/or the ability of such high doses to reduce edema and subsequent ischemia at the affected sites.10 Prostatic carcinoma is the second most common cancer in men and is currently receiving much attention from both medical and public sources. It is infrequently associated with cranial nerve palsies, which usually occur many years after the initial diagnosis. The metastatic lesions either compress or infiltrate the affected nerves.11 At the present time metastatic prostate carcinoma remains incurable. However the use of combined androgen blockade seems to improve survival and quality of life. For painful bone lesions, external beam radiotherapy, bisphosphonates, and strontium 89 or samarium 153 provide pain relief.12 The use of combination chemotherapy to improve survival in hormone refractory prostate cancer has also been receiving a lot of attention.13 If metastatic prostatic carcinoma is causing cranial nerve deficits, radiotherapy seems to result in a beneficial response with either complete or partial resolution of these deficits in most patients14, 15, 16 Therefore it is felt that radiotherapy does offer a palliative treatment with a short term of improved quality of life for these patients. Svare believes radiotherapy should be started as soon as possible after the diagnosis of cranial nerve dysfunction because the longer the symptom persists the poorer the result.1 It is not well documented if the newer hormonal treatments and chemotherapy for metastatic prostate carcinoma have any effect on the cranial nerve deficit. In conclusion, the ophthalmologist should take a careful history including neurological

Symptoms from men with cranial nerve palsies. Those patients with multiple progressive or persistent cranial nerve palsies merit further investigation including PSA levels and possibly a contrast CT scan with bone windows to rule out sinister underlying causes of these symptoms.

**REFERENCES**


1 Kurzer A, Patel MP. Superior orbital fissure syndrome associated with fractures of the zygoma and orbit. Plast Reconstr Surg 1979;64 (5):715–719

2 Acarturk S, Seku.olu T, Kesiktäs E. Mega dose corticosteroid treatment for traumatic superior orbital fissure and orbital apex syndromes. Ann Plast Surg 2004;53(1):60–64

3. Superior Orbital Fissure Syndrome: A Case Report Heath H. Evans, D.D.S. 1 Bradley A. Wurth, D.M.D. 1 Kevin J. Penna, D.D.S. 1

4.Rohrich RJ, Hackney FL, Parikh RS. Superior orbital fissure syndrome: current management concepts. J Craniomaxillofac Trauma 1995;1(2):44–48

5. Chen CT, Wang TY, Tsay PK, Huang F, Lai JP, Chen YR. Traumatic superior orbital fissure syndrome: assessment of cranial nerve recovery in 33 cases. Plast Reconstr Surg 2010;126(1): 205–212

6 Hedstrom J, Parsons J, Maloney PL, Doku HC. Superior orbital fissure syndrome: report of case. J Oral Surg 1974;32(3):198–201

7 Zachariades N, Vairaktaris E, Papavassiliou D, Papademetriou I, Mezitis M, Triantafyllou D. The superior orbital fissure syndrome. J Maxillofac Surg 1985;13(3):125–128

8 Campiglio GL, Signorini M, Candiani P. Superior orbital fissure syndrome complicating zygomatic fractures. Pathogenesis and report of a case. Case report. Scand J Plast Reconstr Surg Hand Surg 1995;29(1):69–72

9 Chen CT, Wang TY, Tsay PK, Huang F, Lai JP, Chen YR. Tramatic superior orbital fissure syndrome: assessment of cranial nerve recovery in 33 cases. Plast Reconstr Surg 2010;126(1): 205–212

10 Hall ED, Braughler JM. Glucocorticoid mechanisms in acute spinal cord injury: a review and therapeutic rationale. Surg Neurol 1982;18(5):320–327

11 Svare A, Fossa SD, Heier MS. Cranial nerve dysfunction in metastatic cancer of the prostate. Br J Urol 1988; 61: 441–444

12 Auclerc G, Antoine EC, Cajfinger F, Brunet-Pommeyrol A, Agazia C, Khayat D. Management of advanced prostate cancer. Oncologist 2000; 5: 36–44

13 Milliken RE. Chemotherapy of advanced prostatic carcinoma. Semin Oncol 1999: 26: 185–191

14 Cullom ME, Savino PJ. Adenocarcinoma of the prostate presenting as a third nerve palsy. Neurology 1993; 43: 2146–2147

15 Ransom DT, Dinapoli RP, Richardson RL. Cranial nerve lesions due to base of the skull metastases in prostate carcinoma. Cancer 1990; 65: 586–589

16 Seymore CH, Pepples WJ. Cranial nerve involvement with carcinoma of the prostate. Urology 1998; 31: 211–213