



A Case Series on Decompensated Chronic Liver Disease with Atrial Fibrillation in Elderly

G. Divya*, K. Uma Kalyani and S. Deepa

Department of Geriatric Medicine, National Centre of Ageing, Madras Medical College, Chennai - 600032, Tamil Nadu, India; divyatvg98@gmail.com

Abstract

Liver cirrhosis patients are more prone to bleeding because the liver is involved in major production of coagulation and anticoagulation proteins. Also, there will be thrombocytopenia secondary to splenomegaly which increases bleeding risk. To treat patients with liver cirrhosis and atrial fibrillation with anticoagulants is complicated in so many ways. In this case series, we discussed three case scenarios of decompensated liver disease associated with atrial Fibrillation where decision making in initiating anticoagulants needed so many considerations.

Keywords: Anticoagulation, Atrial Fibrillation, Liver Cirrhosis, Thrombosis

1. Introduction

Atrial fibrillation is the most common arrhythmia in older people, and the risk of ischemic stroke is higher in this population¹. Patients with decompensated liver disease associated with atrial fibrillation are at an increased risk of both thrombotic and bleeding complications. Atrial Fibrillation (AF) is an increasingly recognized comorbidity in patients with liver cirrhosis, mainly associated with non-alcoholic fatty liver disease and alcohol-associated liver disease, affecting both quality of life and prognosis¹. On the other hand, cirrhosis is associated with an elevated risk of both thrombosis and bleeding, making decisions about anticoagulation therapy very challenging. We have discussed 3 case scenarios in whom the decision to initiate anticoagulants in a decompensated liver disease patients were difficult and challenging. This is to sensitise the physicians treating the older patient of the complexity involved in making treatment decisions.

2. Aim and Objectives

To describe the difficulties in initiating the anticoagulants in liver cirrhosis patients with atrial fibrillation.

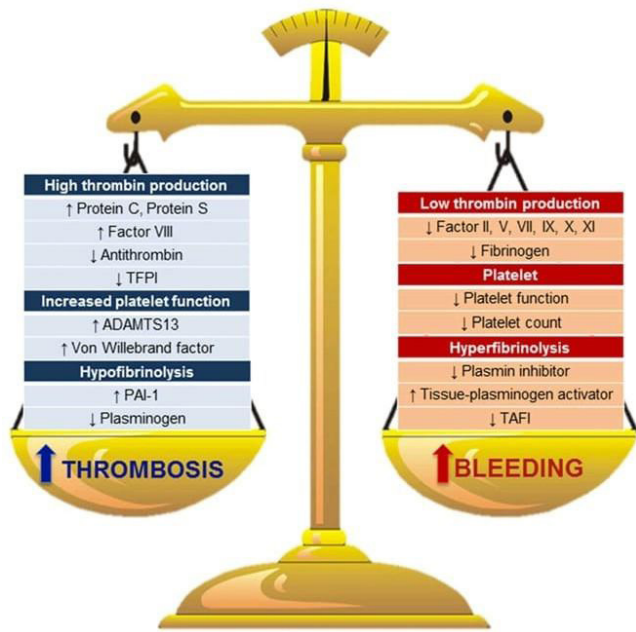
3. Review of Literature

Patients with atrial fibrillation should be given anticoagulants to prevent thromboembolic complications, especially stroke². At the same time because of the risk of bleeding with anticoagulants, their use should be limited to patients whose thrombotic risk is more than bleeding risk². Patients with liver cirrhosis were thought to be prone to an increased bleeding risk because of thrombocytopenia and altered coagulation protein levels.

Patients with cirrhosis are no longer considered prone to bleeding based on their coagulative parameters but are rather thought to be in a less stable, yet still normal, coagulative state, which can be defined as “rebalanced haemostasis.” Patients with compensated liver cirrhosis have a nearly normal coagulative balance unless it has been affected by infection or acute kidney injury³ in a normal individual, there is a haemostatic balance between coagulant and anticoagulant proteins. In liver cirrhosis, the synthesis of both procoagulant and anticoagulant proteins is reduced, a condition collectively termed rebalanced homeostasis—a fragile coagulation state⁴

Whenever infection, acute kidney injury, or dehydration occurs in a patient, the risk of both bleeding

*Author for correspondence



Reference article 3

and thrombosis increases at any time. Against this backdrop of altered coagulation and the increased risk of thrombotic events in liver disease with atrial fibrillation, treating patients with anticoagulants—especially older individuals—is particularly challenging for physician⁴

In patients with compensated liver cirrhosis, bleeding (mostly variceal) is usually the consequence of worsening portal hypertension. The onset and progression of chronic liver failure are associated with derangements in coagulative balance. Modification in the equilibrium between thrombotic and antithrombotic proteins can result in a thrombotic rather than a hemorrhagic condition.

There is evidence that activation of the coagulative cascade plays a role in sustaining chronic liver injury.

4. Material and Methods

Case Series

Case 1

A 67 year old female patient who was a known case of CAD/ heart failure with preserved ejection fraction 55%/DCLD with portal hypertension s/p EVL / hypothyroidism presented with complaints of breathlessness, abdominal distension, swelling of legs, decreased appetite for 3 weeks with h/o reduced urine output O/E patient was conscious, oriented, dyspnoic

and tachypnoic, icterus present , bilateral pitting pedal edema present, no lymphadenopathy.

BP -100/60mmhg, PR - 112/min, irregularly irregular. RR - 22/min JVP not elevated CVS S1, S2 present .pulse deficit - 20/min,

RS - Bilateral NVBS present.

Abdomen: uniformly distended , fluid thrill present. No organomegaly. Investigation platelet - 58000. Renal function test - within normal limits Liver function test: Albumin 2.3, Total Billirubin 6.8, direct Billirubin 3.2, prothrombin time - 27.7 INR - 2.58.

ECG : Rate 120/min, irregular in rhythm absent p wave. Suggestive of Atrial fibrillation.

Echo: concentric LVH, mild global hypokinesia of left ventricle, mild LVSD Ef 50%. USG Abdomen: suggestive of DCLD, moderate to severe ascites.

Upper GI scopy: portal hypertensive gastropathy, duodenopathy and grade 2 esophageal varices. CHA2DS2VASc score 2, HAS BLED -3 CHILD PUGH score 13 C

Case 2

A 64 year old female patient k/c/o DCLD presented with complaints of swelling of legs, shortness of breath , altered sensorium O/E, patient drowsy E1V5M3, pallor present, Bilateral pitting pedal edema present

BP 110/60mmhg, PR- 82/min, CVS S1, S2 present. RS - bilateral NVBS present. Bilateral basal creps present. P/A soft, distended, splenomegaly present.

ECG -HR - 154, irregular rhythm, absent p wave. Investigation HB -8, Total count - 6210, platelet - 71,000 Urea 113, creatinine - 1.19

TB - 7.08, DB - 3.88, ALP- 248, ALT- 33, AST - 49, GGT - 18, serum Albumin - 2.6, Globulin -3.9 A/G ratio 0.067

PT - 28.1, INR - 2.36

viral markers - negative

ECHO: Global hypokinesia of left ventricle, Ef 30%

USG Abdomen - moderate ascites, splenomegaly. Upper GI endoscopy - grade 2 esophageal varices. CHA2DS2VASc - 2,

HAS - BLED 3, CHILD PUGH score 15 c.

Case 3

A 69 year old female patient k/c/o DCLD / T2dm presented with complaints of palpitations, shortness of breath, giddiness for 3 days

O/E, patient conscious, oriented, pallor present, Bilateral pitting pedal edema present

BP 100/60mmhg, PR- 78/min, CVS S1, S2 present. RS - bilateral NVBS present. P/A soft, distended. ECG HR - 144/min, irregular rhythm absent p wave.

Investigation HB -8.5, Total count - 8410, platelet - 96,000, Urea 40, creatinine - 1.1, TB - 5.08, DB -

1.88, ALP- 108, ALT- 28, AST - 29, serum Albumin - 2.9,

PT - 20.1, INR - 2.0

viral markers - negative

ECHO: Normal left ventricular function, Ef 60%

USG Abdomen - moderate ascites, chronic liver disease. CHA2DS2VASc - 3,

HAS - BLED 3, CHILD PUGH score 11

5. Results (Including Observations)

This case series presents three elderly patient having decompensated liver disease with atrial fibrillation, each exhibiting a difficult clinical scenario to initiate anticoagulants.

Case Scenario 1: Warfarin was not initiated in this patient since the patients baseline INR was high and patient had thrombocytopenia. Patient was not affordable to purchase direct acting oral anticoagulants. So, patient was discharged without anticoagulant. On follow up after 2 weeks, it was informed that patient died at home after sustaining a fall

Case Scenario 2: Anticoagulants couldn't be initiated in this patient since patient had a high baseline INR and there was thrombocytopenia. Also patient was treated in ICU as patient developed pulmonary edema due to cardiac failure. Patient died in ICU.

Case Scenario 3: This patient also had elevated INR and thrombocytopenia. Patient died on the day of admission due to atrial fibrillation.

6. Discussion

Treating atrial fibrillation in patients with Decompensated Liver Disease, that too in an older patient, is very difficult with not much evidence to guide us through. A retrospective longitudinal

study done among US veterans had proven that both warfarin and DOAC in such patients reduced all-cause mortality but with increased bleeding risk among warfarin users⁵. Another study done in Taiwan were nearly 10000 patients who had Liver cirrhosis with atrial fibrillation who received and didn't receive anticoagulants were compared. This study found a net clinical benefit of anticoagulants in preventing stroke in these groups of patients³. But this study included a relatively younger age group patients. In older patients with similar comorbidities, we were not able to initiate anticoagulants as evidenced by above case scenarios. Altered coagulation system in liver disease will cause a baseline elevated INR as shown in studies³.

We also encountered this in our patients. This makes monitoring of Warfarin difficult. Also sophisticated tests to monitor coagulation system is available in only selected centres which are either not feasible or inaccessible for the patients. All three patients had a CHADVasc score of 2 and more and HAS BLED score of 3. All the patients had severe Liver disease as seen by their Child Pugh score of 10-15. Also, all these patients landed in our tertiary care hospital only in advanced stage of their disease where anticoagulation ceases to be more beneficial than risky.

Since warfarin significantly lowers the risk of ischemic stroke in Atrial fibrillation patients with liver cirrhosis, so anticoagulation should be considered for all the patients which is proven in another randomised study in atrial fibrillation with Liver Cirrhosis and Net Clinical Benefit of Oral Anticoagulation⁶.

Also, in nationwide study to directly compare apixaban, rivaroxaban, and warfarin in patients with cirrhosis and non-valvular atrial fibrillation, Rivaroxaban and warfarin were associated with higher hemorrhagic risk supporting apixaban is the preferred anticoagulant in this high-risk population⁷.

7. Summary and Conclusion

“The initiation of anticoagulant therapy for atrial fibrillation in older patients with chronic liver disease is a highly complex issue. Due to the interplay between liver dysfunction and anticoagulant pharmacodynamics, the management of these patients requires careful and individualized decision- making. Given the limited evidence in this population, further

studies that specifically include older patients with chronic liver disease are necessary to address these challenges and optimize treatment approaches.”

8. References

1. Cardiac Arrhythmias. Hazzard's Geriatric Medicine and Gerontology. New York: McGraw Hill; 2608-2618.
2. Atrial Fibrillation: Clinical features, mechanisms and management, Braunwald's Textbook of Cardiovascular Medicine. Elsevier; 1747-60.
3. Turbo L, de Raucourt E, Valla DC, Villa E. Anticoagulation in the cirrhotic patient. JHEP Rep. 2019 16;1(3):227-239. <https://doi.org/10.1016/j.jhepr.2019.02.006> PMID:32039373 PMCID:PMC7001584
4. Ballestri S, Capitelli M, Fontana CM, Arioli D, Romagnoli E, Graziosi C, *et al.* Direct oral anticoagulants in patients with liver disease in the era of non-alcoholic fatty liver disease global epidemic: A narrative review. Adis Journals. 2020. <https://doi.org/10.6084/m9.figshare.11993394>. <https://doi.org/10.1007/s12325-020-01307-z> PMID:32285340 PMCID:PMC7467481.
5. Serper M, Weinberg EM, Cohen JB, Reese PP, Taddei TH, Kaplan DE. Mortality and Hepatic Decompensation in patients with cirrhosis and atrial fibrillation treated with anticoagulation. Hepatology. 2021; 73(1):219-32. Epub 2020;9. <https://doi.org/10.1002/hep.31264> PMID:32267547 PMCID:PMC7541418.
6. Liver cirrhosis in patients with Atrial Fibrillation: Would oral anticoagulation have a net clinical benefit for stroke prevention? J Am Heart Assoc. 2017; 6(6). <https://doi.org/10.1161/JAHA.116.005307> PMID:28645935 PMCID:PMC5669162.
7. Simon TG, Singer DE, Zhang Y, Mastrorilli JM, Cervone A, DiCesare E, Lin KJ. Comparative effectiveness and safety of apixaban, rivaroxaban, and warfarin in patients with cirrhosis and atrial fibrillation : a nationwide cohort study. Ann Intern Med. 2024; 177(8):1028-1038. Epub 2024; 9.. <https://doi.org/10.7326/M23-3067> PMID:38976880 PMCID:PMC11671173.