



Trichoscopic Insights into Rare Inherited Hair Disorders: A Case Series

K. Rajarajan*, H. Dhanaselvi, S. Murugan and V. Sampath

Department of Dermatology, Venereology and Leprosy, Madras Medical College, Chennai - 600010, Tamil Nadu, India; Rajakathiravan97@gmail.com

Abstract

Background: Rare inherited hair disorders pose diagnostic challenges in pediatric dermatology. Trichoscopy, a non-invasive technique, enhances diagnostic accuracy through visualization of hair and scalp abnormalities. **Objective:** To document trichoscopic features of Loose Anagen Syndrome (LAS), Woolly Hair (WH), and Congenital Hypotrichosis (CH) in pediatric patients, highlighting its role in early diagnosis and management. **Methods:** A descriptive case series was conducted at a tertiary dermatology center. Three pediatric patients underwent clinical evaluation, trichoscopy using a HEINE DELTA 30 dermatoscope, and in one case, trichogram analysis. **Results:** LAS showed black dots, single follicular units, perifollicular scaling, and “floppy sock” anagen hairs. WH exhibited variation in shaft diameter, pigment dilution, “crawling snake” appearance, and trichoptilosis. CH revealed vellus hairs, pigment dilution, white and brown globules, and pseudo-reticular pigment network. **Conclusion:** Trichoscopy is a vital, painless diagnostic tool in pediatric trichology, facilitating early detection of inherited hair disorders and guiding genetic evaluation and counseling. Trichoscopy, Loose Anagen Syndrome, Woolly Hair, Congenital Hypotrichosis, Pediatric Hair Disorders, Genetic Alopecia, Dermoscopy, Non-invasive Diagnosis

Keywords: Congenital Hypotrichosis, Inherited Hair Disorders, Loose Anagen Syndrome, Trichoptilosis, Trichoscopy, Woolly Hair

1. Introduction

Inherited hair disorders, though rare, can present with unique clinical and trichoscopic findings that aid in diagnosis. Early diagnosis is crucial in clinical practice for appropriate management and genetic counseling. This case series examines trichoscopic findings in three pediatric patients with different inherited hair disorders: Loose anagen syndrome, woolly hair, and congenital hypotrichosis. Each case highlights the importance of trichoscopy in identifying distinctive features associated with these conditions. Trichoscopy is a non-invasive diagnostic tool that provides detailed visualization of hair and scalp abnormalities. In pediatric patients, trichoscopy is especially valuable

for identifying specific patterns and subtle signs characteristic of inherited hair disorders. Enhances diagnostic accuracy, allowing for earlier and more precise intervention

2. Aim and Objectives

- To analyze and document the trichoscopic features of rare inherited hair disorders in pediatric patients, specifically Loose Anagen Syndrome, Woolly Hair, and Congenital Hypotrichosis.
- To highlight the diagnostic utility of trichoscopy as a non-invasive tool in early identification and management of inherited hair disorders, aiding in clinical decision-making and genetic counseling.

*Author for correspondence

3. Review of Literature

Inherited hair disorders, though uncommon, present significant diagnostic challenges due to their rarity, varied presentation, and overlapping features. The advent of trichoscopy—a non-invasive dermatoscopic examination of hair and scalp—has revolutionized the diagnosis of these conditions. Trichoscopy allows clinicians to observe characteristic hair shaft abnormalities, pigmentation patterns, and follicular changes in vivo, aiding in accurate diagnosis and early intervention. This literature review discusses three rare inherited hair disorders—Loose Anagen Syndrome, Woolly Hair, and Congenital Hypotrichosis—with a focus on their trichoscopic features and diagnostic implications.

3.1 Loose Anagen Syndrome (LAS) Clinical Overview

Loose Anagen Syndrome is a benign, non-scarring alopecia characterized by hair that is easily and painlessly pulled out due to defective anchoring of the hair shaft in the follicle. It predominantly affects young children, particularly females, and often presents with diffuse hair thinning and hair that fails to grow long¹.

Trichoscopic Features:

Trichoscopy reveals key findings including:

Black dots: Indicating hair broken at the scalp level. Perifollicular scaling: Suggestive of localized inflammation.

Single hair follicular units: Which may reflect decreased follicular density.

Floppy sock appearance: On trichogram, the anagen hair shows a misshapen, ruffled cuticle and a poorly developed bulb resembling a loose sock².

These features provide significant clues in differentiating LAS from other causes of pediatric alopecia like alopecia areata or trichotillomania. Maxfield *et al.*, emphasize the importance of combining clinical history with trichoscopic findings for a confident diagnosis¹.

3.2 Genetics and Pathophysiology

LAS may occur sporadically or follow an autosomal dominant inheritance pattern. The underlying defect

lies in the improper keratinization of the inner root sheath, reducing hair anchorage³.

3.3 Woolly Hair (WH) Clinical Overview

Woolly Hair is characterized by tightly coiled, hypopigmented, and fragile hair, usually present from birth. It may appear in isolated patches or affect the entire scalp. While it may occur in isolation, it is also a feature of several syndromes like Naxos and Carvajal-Huerta syndromes, which involve cardiac and cutaneous anomalies⁴.

Trichoscopic Features:

Trichoscopy in WH typically reveals:

Variation in hair shaft diameter and pigment: A hallmark of structural hair shaft abnormalities. Kinking and coiling of hair shafts: Leading to the “crawling snake” appearance⁵.

Trichoptilosis: Splitting of distal ends of hair due to fragility.

In WH, pigment dilution and gray hair shafts are common, and the hair may appear translucent or orange-brown under magnification. These features help distinguish WH from other genetic hair disorders like pili torti or monilethrix⁶.

3.4 Genetic and Syndromic Associations

WH may be inherited in an autosomal recessive or dominant pattern. When associated with systemic features (e.g., arrhythmogenic right ventricular cardiomyopathy in Naxos syndrome), genetic testing and multidisciplinary evaluation are essential for comprehensive care⁴.

3.5 Congenital Hypotrichosis (CH) Clinical Overview:

Congenital Hypotrichosis is a group of disorders defined by sparse scalp and body hair present at birth or developing in early infancy. It may be isolated or part of complex syndromes involving ectodermal, skeletal, or neurological abnormalities⁷.

Trichoscopic Features:

Distinctive features seen under trichoscopy include:

Predominance of vellus hairs: Especially in the scalp and eyebrows.

Pigment dilution and white dots/globules: Indicating absent or miniaturized follicles. Pseudoreticular pigment network: An unusual but specific pattern.

Brown dots/circles: Representing residual pigmentation or follicular plugging.

These findings, combined with clinical absence of terminal hair, support the diagnosis of CH. Rakowska et al. noted that trichoscopy can reveal follicular abnormalities long before they become apparent on clinical exam, enhancing early diagnosis⁸.

3.6 Genetic Considerations

CH encompasses a spectrum of disorders. Some forms, such as hypotrichosis simplex or Marie Unna hypotrichosis, follow Mendelian inheritance, while others occur in the context of chromosomal or metabolic syndromes. Genetic counseling is crucial, particularly in consanguineous families⁹.

Role of Trichoscopy in Diagnosis and Management

Trichoscopy has become an indispensable tool in diagnosing inherited hair disorders. Unlike light microscopy, which requires hair extraction and preparation, it allows visualization of hair shaft morphology, pigment changes, follicular patterns, and peri-follicular abnormalities without patient discomfort. For pediatric patients, this is particularly advantageous. Several studies have emphasized its role not just in diagnosis but also in monitoring disease progression and treatment response. Olszewska et al. proposed standardized trichoscopic criteria for various inherited hair disorders, streamlining clinical assessment¹⁰.

Trichoscopy provides a critical, non-invasive window into the structure and pathology of rare inherited hair disorders. By identifying unique hair and follicular abnormalities, it facilitates early and accurate diagnosis of conditions such as Loose Anagen Syndrome, Woolly Hair, and Congenital Hypotrichosis. When combined with clinical history and genetic insights, trichoscopy supports individualized patient management, early intervention, and appropriate genetic counseling. As its utility expands, clinicians must familiarize themselves with trichoscopic patterns to enhance diagnostic precision and patient outcomes in pediatric trichology.

4. Material and Methods

- Study Design and Setting
- This is a descriptive observational case series conducted in the department of dermatology at Madras Medical College, focusing on the trichoscopic evaluation of rare inherited hair disorders in pediatric patients.
- Setting: Institute of DVL outpatient department.
- Data Collection:
- Detailed clinical history was recorded, including onset, progression of hair loss, family history, and systemic symptoms. A complete dermatological examination of the scalp, eyebrows, eyelashes, and body hair was conducted.
- Trichoscopic Examination: All patients underwent trichoscopy using a handheld dermatoscope (HEINE DELTA 30) in both polarized and non-polarized modes.
- Statistical Analysis: Descriptive statistics were used to analyze the data.
- Trichogram: In the case of suspected LAS, a trichogram was performed. Hair was gently pulled from the scalp and examined microscopically for hair bulb morphology to detect the “floppy sock” appearance typical of dystrophic anagen hairs.

5. Results (Including Observations)

5.1 Case1-Loose Anagen Syndrome

- A 9 years old female, born to consanguineous parents, presented with complaints of excessive shedding of scalp hair from 3 years of age.
- The mother initially noticed difficulty to comb hair with easily pluckable hair leading to diffuse thinning of scalp hair.
- Parents complained that child’s hair doesn’t grow long which seldom required haircut.
- No similar complaints in family members.

5.1.1 Dermatological Examination

- On examination, scalp hair is black in colour, diffusely thin, dry and frizzy.
- No signs of scaling, inflammation or scarring of the scalp. Eyebrow hairs, eyelashes, and body hair are normal.

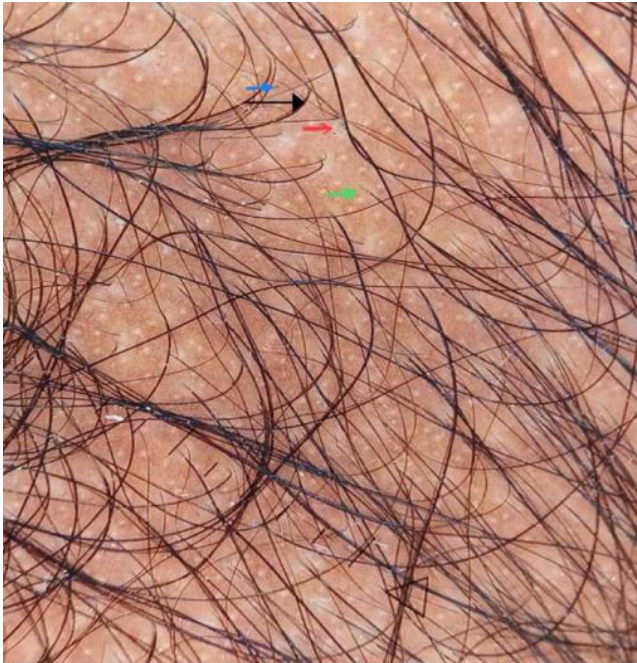

Figure 1. Trichoscopy of loose anagen syndrome.

- Teeth, mucosa, nails, palms and soles are normal. There are no ocular, cardiac, neurological or skeletal defects.
- Hair pull test with gentle traction revealed painless extraction of hairs
- Trichoscopy shows perifollicular fine scaling (red arrow), (Figure 1)
- numerous single follicular units (green arrow),
- and black dots. (blue arrow)
- Trichogram shows predominance of dystrophic anagen hairs with squared off anagen bulb and ruffled cuticle giving floppy sock appearance consistent with Loose anagen syndrome (Figure 2).

5.2 Case 2- Woolly Hair

- A 9-year-old boy presented with thin, short, sparse, brown hair since birth.
- History of decreased hair volume since birth.
- There were no similar complaints in the family members.

5.2.1 Dermatological Examination

- Examination revealed dull, lustreless, tightly coiled orange-brown hairs with diffuse thinning distributed over the scalp.

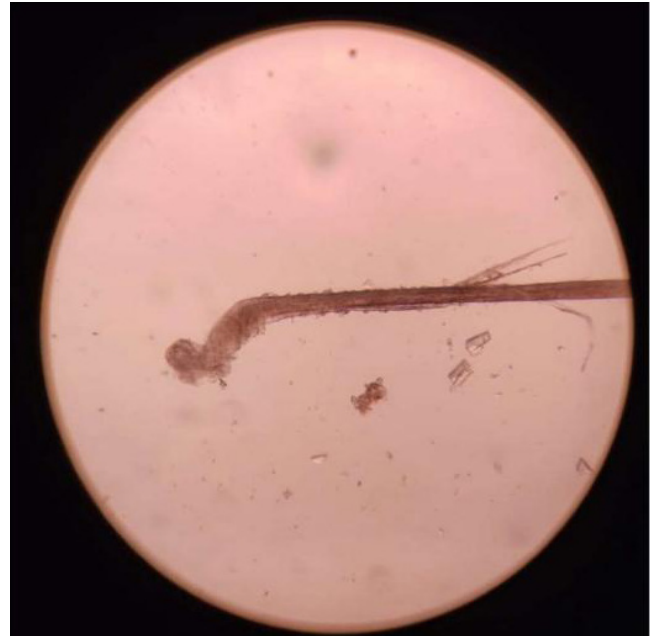

Figure 2. Trichogram of loose anagen syndrome.

- There were no signs and symptoms suggestive of cardiac abnormalities or any other systemic involvement.
- Eyebrow hairs, eyelashes, and body hair are normal.
- Teeth, mucosa, nails, palms and soles are normal. There is no ocular, cardiac, neurological or skeletal defects.
- Hair pull test with gentle traction revealed painless extraction of hairs
- Trichoscopy showed multiple grey hairs, pigment dilution, vellus hairs, and variation in hair shaft diameter and pigment (Figure 3).
- Trichoptilosis (green circle), and a “crawling snake” appearance (red circle), kinking (red arrow) was noted, consistent with Woolly Hair, a condition involving tightly coiled and fragile hair (Figures 4 and 5).

5.3 Case 3- Congenital Hypotrichosis

- A 10-year-old boy born to consanguineous parents presented with spontaneous scalp hair loss from 3 months of age.
- History of absence of eyebrows and eye lashes since birth.
- There were no similar complaints in the family members.

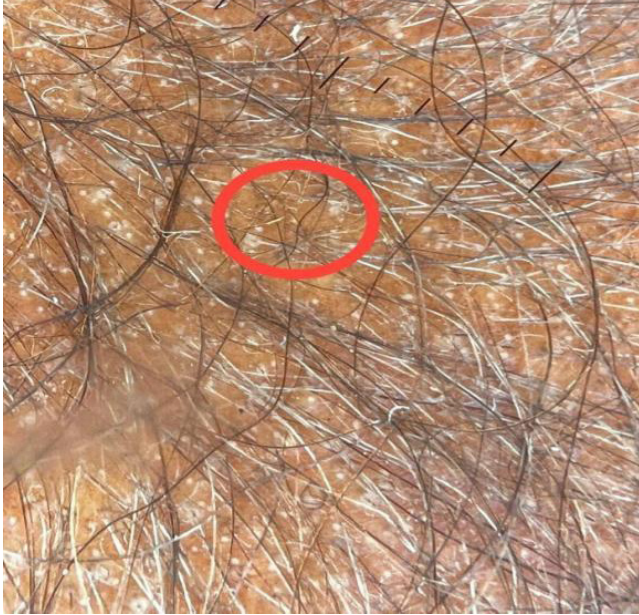

Figure 3. Trichoscopy of woolly hair (1).

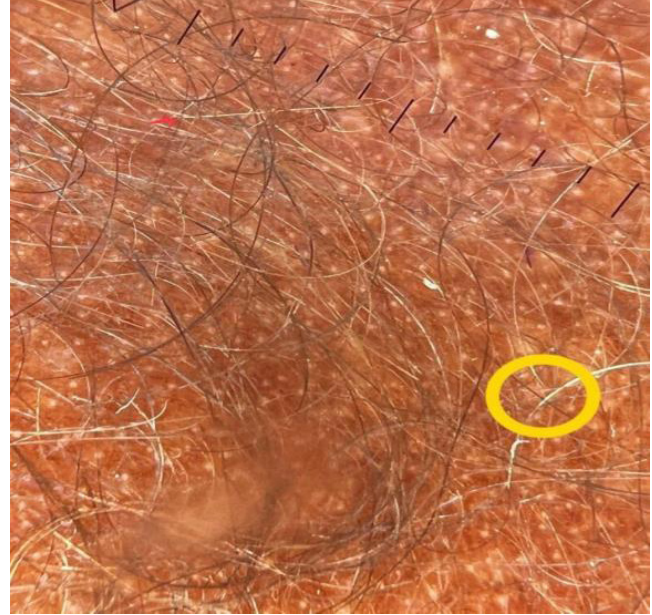

Figure 5. Trichoscopy of woolly hair (3).

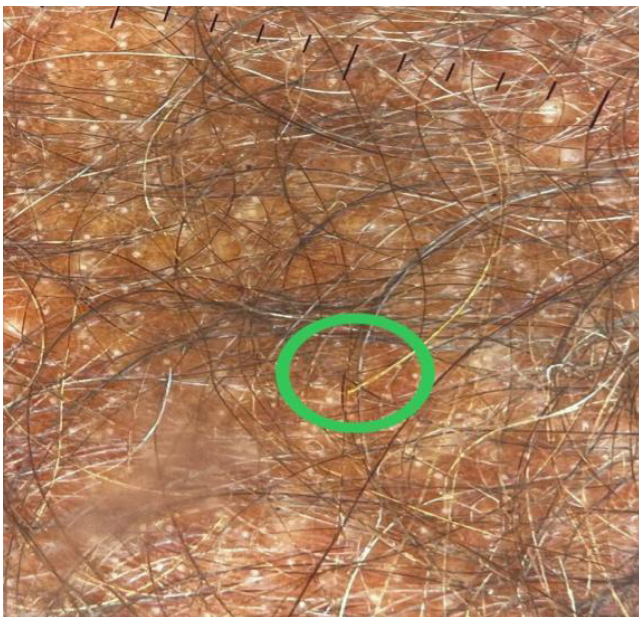

Figure 4. TRICHOSCOPY OF WOOLLY HAIR (2).

5.3.1 Dermatological Examination

- On examination diffuse hair loss noted over entire scalp with vellus hair in few areas
- Loss of eyebrows present.
- Hair follicles with vellus hair noted in the body.
- Teeth, mucosa, nails, palms and soles are normal. There is no ocular, cardiac, neurological or skeletal defects.

- Hair pull test with gentle traction revealed painless extraction of hairs.
- Scalp - vellus hair (red arrow), pigment diluted hair, few terminal hairs (green arrow) present
- Multiple regularly arranged white dots and white globules.
- Multiple brown dots and brown globules, pseudo reticular pigment pattern, brown circles present
- Hairs of varying diameter present.
- Eyebrows- more of vellus hair (red arrow), no terminal hair, features consistent with congenital hypotrichosis (Figures 6 and 7).

6. Discussion

- Loose anagen syndrome is a hair shaft disorder characterized by increased fragility and excessive shedding of hair due to poor adhesion between cuticle and inner root sheath.
- It is inherited as autosomal dominant disorder or occurs sporadically.
- Inherited woolly hair usually involves the entire scalp and can occur either in the absence of other physical findings or in association with other syndromes.
- The reported syndromes which can be associated with woolly hair are the Naxos syndrome, the Carvajal-Huerta syndrome, the ectodermal

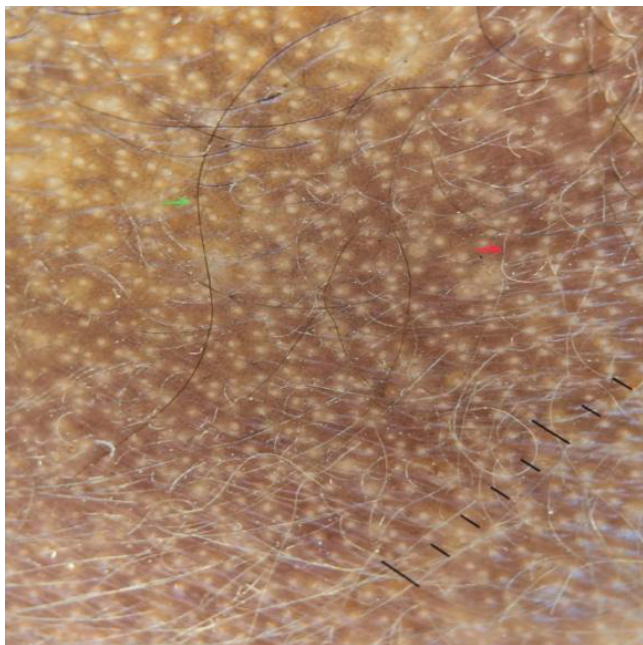


Figure 6. Trichoscopy of Congenital Hypotrichosis (1).

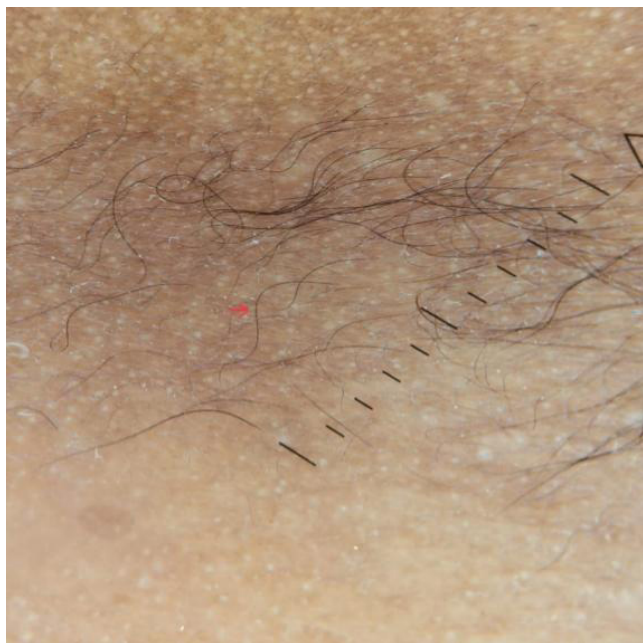

Figure 7. Trichoscopy of congenital hypotrichosis (2).

dysplasia-skin fragility, the woolly hair/hypotrichosis, and the trichohepatoenteric syndrome.

- Congenital hypotrichosis may occur either in isolation or may be associated with other features, including epilepsy, chromosomal abnormalities, inborn errors of metabolism, ocular, ectodermal, or skeletal abnormalities.

- If any associations are identified, workup for a syndromic cause should be performed in collaboration with a pediatrician and genetic counseling with the help of a geneticist may be appropriate depending on the diagnosis.

7. Summary

This case series explores the trichoscopic features of three rare inherited hair disorders—Loose Anagen Syndrome (LAS), Woolly Hair (WH), and Congenital Hypotrichosis (CH)—in pediatric patients. This study emphasizes the role of trichoscopy as a non-invasive, diagnostic tool that enhances early identification and management of such conditions.

Loose Anagen Syndrome presents in children with hair that is easily and painlessly extractable. Trichoscopy revealed black dots, perifollicular scaling, single follicular units, and a distinctive “floppy sock” appearance on trichogram, indicative of poorly anchored anagen hairs.

Woolly Hair is marked by tightly coiled, hypopigmented, fragile hair present from birth. Trichoscopic examination showed variation in shaft diameter and pigment, pigment dilution, kinking, “crawling snake” appearance, and trichoptilosis. These features are essential for distinguishing WH from other structural hair abnormalities.

Congenital Hypotrichosis involves sparse scalp and body hair since infancy, often with syndromic associations. Trichoscopy showed predominant vellus hairs, white and brown globules, pseudo-reticular pigment pattern, and pigment dilution, aiding early detection.

The study concludes that trichoscopy is a vital, non-invasive diagnostic modality in pediatric trichology. It provides early visual cues to differentiate inherited hair disorders and supports clinical and genetic correlation for better patient care and counseling.

8. Conclusion

- Trichoscopy is a valuable diagnostic tool for rare inherited hair disorders.
- Trichoscopy allows a simple, quick, and non-invasive examination of a single hair or multiple hairs in vivo which is not possible with a light microscope.

- This case series highlight the importance of recognizing trichoscopic patterns in pediatric cases.
- These cases also illustrate the need for clinicians to consider genetic evaluation, especially in pediatric patients, to confirm diagnoses, inform families, and plan management

9. References

1. Maxfield L, Cook C. Loose Anagen Syndrome. In: StatPearls. Treasure Island (FL): StatPearls Publishing; 2024. <https://www.ncbi.nlm.nih.gov/books/NBK526030/>
2. Dhurat RP, Deshpande DJ. Loose anagen hair syndrome. *Int J Trichology*. 2010; 2(2):96-100. <https://doi.org/10.4103/0974-7753.77513> PMID:21712911 PMCID:PMC3107966.
3. Ramot Y, Zlotogorski A. The twisting tale of woolly hair: A trait with many causes. *J Med Genet*. 2015; 52(4):217-223. <https://doi.org/10.1136/jmedgenet-2014-102630>
4. Vasudevan B, Verma R, Badad A, Pragasam V. A rare case of woolly hair with unusual associations. *Indian Dermatol Online J*. 2013; 4(3):222. <https://doi.org/10.4103/2229-5178.115524> PMID:23984241 PMCID:PMC3752483.
5. Olszewska M, Rudnicka L, Rakowska A, Kowalska OE, Slowinska M. Trichoscopy. *JAMA Dermatology*. 2008;144(8):1007. <https://doi.org/10.1001/archderm.144.8.1007>
6. Rakowska A, Slowinska M, Kowalska OE, Rudnicka L. Trichoscopy in genetic hair shaft abnormalities. *J Dermatol Case Rep*. 2008; 2:14-20. <https://doi.org/10.3315/jdcr.2008.1009>
7. Priolo M, Lagana C. Ectodermal dysplasias: A new clinical-genetic classification. *J Med Genet*. 2001; 38(9):579-585. <https://doi.org/10.1136/jmg.38.9.579> PMID:11546825 PMCID:PMC1734928.
8. Rakowska A, Slowinska M, Kowalska-Oledzka E, Olszewska M, Rudnicka L. Trichoscopy in genetic hair shaft abnormalities. *J Dermatol Case Rep*. 2008; 2(2):14-20. <https://doi.org/10.3315/jdcr.2008.1005> PMCID:PMC3157774.
9. Shimomura Y, Christiano AM. Genetics of hair loss disorders. *Semin Cutan Med Surg*. 2010; 29(1):4-10. <https://doi.org/10.1016/j.sder.2010.01.002> PMID:20430302.
10. Olszewska M, Rakowska A, Slowinska M, Rudnicka L. Trichoscopy: A new method for diagnosing hair loss. *J Drugs Dermatol*. 2008; 7(7):651-654. <https://doi.org/10.1001/archderm.144.8.1007> PMID:18711072.