



# A Case Series of Four Patients with Inflammatory Myositis Under a General Medicine Unit in a Tertiary Care Centre in South India

Krupa Devakumar<sup>1</sup>, Vignesh Kumar Chandiraseharan<sup>\*1</sup>, Anna Paul<sup>1</sup>, Tina George<sup>1</sup>, Thambu David Sudarsanam<sup>1</sup>, Mohan Jambugulam<sup>1</sup>, Prabhu Ram<sup>1</sup>, Amita Jacob<sup>1</sup>, J. Ranjani<sup>2</sup>, Meera Thomas<sup>2</sup>, Geeta Chacko<sup>2</sup>, Ajith Sivadasan<sup>3</sup> and Prasanna Samuel<sup>4</sup>

<sup>1</sup>Department of General Medicine, Christian Medical College, Ida Scudder Road, Vellore - 632004, Tamil Nadu, India; vigneshmmc02@gmail.com

<sup>2</sup>Department of Pathology, Christian Medical College, Ida Scudder Road, Vellore - 632004, Tamil Nadu, India

<sup>3</sup>Department of Neurology, Christian Medical College, Ida Scudder Road, Vellore - 632004, Tamil Nadu, India

<sup>4</sup>Department of Biostatistics, Christian Medical College, Ida Scudder Road, Vellore - 632004, Tamil Nadu, India

## Abstract

**Background:** Inflammatory myositis comprises a spectrum of immune-mediated muscle disorders with varied clinical presentations and outcomes. Limited data exist from general medicine wards in India, especially regarding their real-world management and prognostic factors. **Objectives:** **1.** To describe the clinical profile of four patients admitted with inflammatory myositis. **2.** To describe the management strategies including diagnosis and treatment. **3.** To describe the outcomes of the affected patients. **Methods:** In this case series, we included patients diagnosed with inflammatory myositis and admitted under a unit in general medicine in a tertiary care center in South India between 2023 and 2024. Data were extracted from electronic medical records and entered into a clinical research form. The findings were tabulated and discussed. The study was approved by the Institutional Ethics Committee, (IRB Min No.2502155). **Results:** All patients (n = 4) presented with proximal symmetrical muscle weakness, with symptom duration ranging from 2 to 36 months. Autoantibody profiling revealed: **1.** Anti-SRP positivity in 2 patients (suggestive of immune-mediated necrotizing myopathy), **2.** Anti-Mi-2 in dermatomyositis, **3.** Anti-Ro52 in polymyositis. MRI confirmed inflammatory myositis in most cases, and muscle biopsy correlated with serological findings. All patients received corticosteroids; adjunct therapies included IVIg and cyclophosphamide. Three patients showed good clinical response with no relapse or major complications. One patient succumbed to the illness. **Conclusion:** Inflammatory myopathies present with heterogeneous clinical and immunological features. Integration of clinical evaluation, serology, MRI, and biopsy is vital for diagnosis. Early immunosuppression, including corticosteroids and second-line agents, can result in favorable outcomes-even in aggressive subtypes like anti-SRP-associated necrotizing myopathy.

**Keywords:** Autoantibodies, Dermatomyositis, Immunosuppressive Therapy, Inflammatory Myositis, Necrotizing Myopathy, Polymyositis, South India

## 1. Introduction

Inflammatory myositis comprises a spectrum of immune-mediated muscle disorders with varied

clinical presentations and outcomes. Limited data exist from general medicine wards in India, especially regarding their real-world management and prognostic factors.

*\*Author for correspondence*

## 2. Aim and Objectives

### 2.1 Objectives

- To describe the clinical profile of four patients admitted with inflammatory myositis.
- To describe the management strategies including diagnosis and treatment.
- To describe the outcomes of the affected patients.

## 3. Review of Literature

Inflammatory myopathies are a group of rare, chronic muscle disorders characterized by muscle inflammation, progressive weakness, and, sometimes, pain. These conditions can affect both children and adults, leading to skeletal muscle impairment. Key subtypes include polymyositis, dermatomyositis, inclusion body myositis, and necrotizing autoimmune myopathy. The pathophysiology is primarily autoimmune, with immune responses targeting muscle fibres and connective tissue, disrupting normal function.

A Pune-based study involving 114 patients with inflammatory myositis found 36 Dermatomyositis (DM), 28 Polymyositis (PM), and 41 overlap CTD (OCTD) cases. The mean age of onset was 33-40 years, with a female predominance. Proximal muscle involvement was common, with Raynaud's phenomenon and DM rash more frequent in OCTD. Autoantibodies were detected in most patients, and standard treatments like steroids, methotrexate, and hydroxychloroquine showed positive responses. Mortality was reported in four patients due to disease complications<sup>1</sup>.

### 3.1 Role of Autoantibodies

Myositis-Specific Autoantibodies (MSAs) help distinguish phenotypic subsets of inflammatory myopathies. These autoantibodies contribute to myofiber injury and skin inflammation, influencing disease severity. Early identification of MSAs is crucial for prognosis and disease management, aiding in predicting disease progression and systemic involvement. They also help guide personalized treatments, improving patient outcome<sup>2</sup>.

A study in Brazil found that 34.4% of patients had myositis-specific autoantibodies, and 41.4% had

myositis-associated autoantibodies. Anti-Ro-52 was the most common, followed by anti-Jo-1 and anti-Mi-2. Associations included anti-Mi-2 with photosensitivity and anti-Jo-1 with pulmonary complications<sup>3</sup>.

Management Glucocorticoids remain the first-line treatment for myositis, often combined with other immunosuppressive agents in early disease stages. Supervised exercise, alongside pharmacological treatment, can improve outcomes. Rituximab shows potential in patients with specific autoantibodies, and other biologic therapies are being explored in clinical trials<sup>4</sup>.

### 3.2 Prognosis

Despite advances in management, mortality in inflammatory myopathies remains high, primarily due to cancer and cardiac involvement, which are significant prognostic factors<sup>5</sup>.

Patients with inflammatory myopathy often present initially to the General Medicine department due to diagnostic uncertainty. In this case-series, we have aimed at describing the clinical profile of these patients, line of evaluation, management and the in-hospital outcome.

## 4. Material and Methods

This is a retrospective case series of patients admitted with inflammatory myopathy in a general medical unit between 2023-24. We contacted the department of medical records for hospital numbers of patients with the following keywords in their final diagnosis- Inflammatory myositis, dermatomyositis, inclusion body myositis, polymyositis, necrotising myositis, myopathy, myositis, elevated CPK under evaluation. The patients were identified from their hospital numbers and records reviewed. The patients who fulfilled the diagnosis of an inflammatory myopathy were included in this case series. The clinical characteristics, laboratory investigations, radiological and histopathological features were captured from the electronic medical records. The features were compared, contrasted and tabulated.

## 5. Results (Including Observations)

### Case 1

A 41-year-old female from West Bengal presented with a 2-month history of progressive proximal muscle

weakness and joint pain, without systemic features such as rash, dysphagia, or respiratory symptoms. She had no significant comorbidities or family history of autoimmune disease. Examination showed features of proximal muscle weakness. Laboratory investigations showed a serum CPK of 1537 IU/L and positive ANA. EMG was consistent with a myopathic pattern, and Anti- Ro52 antibodies were detected on myositis panel.

Muscle biopsy revealed perivascular inflammation without perifascicular atrophy or necrosis, favoring a diagnosis of polymyositis. MRI findings were not available. She was treated with oral corticosteroids and IVIg for 12 months. No cytotoxic or additional immunosuppressive agents were used. The patient achieved significant clinical improvement in muscle strength and normalization of CPK. She remained relapse-free with no complications or mortality reported during the follow-up.

### Case 2

A 37-year-old female from Tamil Nadu presented with progressive symmetrical proximal muscle weakness of 24 months duration, without associated cutaneous signs or systemic complaints. There was no personal or family history of autoimmune disorders. Examination showed features of proximal muscle weakness. Her CPK was mildly elevated at 491 IU/L, ANA was negative, and EMG showed inflammatory changes.

Serological testing revealed Anti-SRP antibody positivity, a marker associated with Immune-Mediated Necrotizing Myopathy (IMNM). MRI showed diffuse increased uptake in all muscles, consistent with widespread myositis. Muscle biopsy was not performed or unavailable. She was initiated on steroids without additional immunosuppressants. She subsequently succumbed to her illness shortly after initiation of therapy.

### Case 3

A 27-year-old male from Bangladesh presented with 6 months of proximal muscle weakness, without rash, dysphagia, or systemic features. He had no known comorbidities. Examination showed features of proximal muscle weakness. Laboratory evaluation showed a markedly elevated CPK (5826 IU/L) and

positive ANA. EMG findings were consistent with a myopathic process.

He tested positive for Anti-Mi-2 antibodies, which are strongly associated with classic dermatomyositis. MRI revealed inflammatory changes, and muscle biopsy showed perifascicular atrophy, a defining feature of dermatomyositis. The patient was treated with oral corticosteroids and cyclophosphamide (4 months). No biologics or IVIg were used. He had a robust clinical response with normalization of CPK and functional recovery. Follow-up showed no relapse, complications, or mortality.

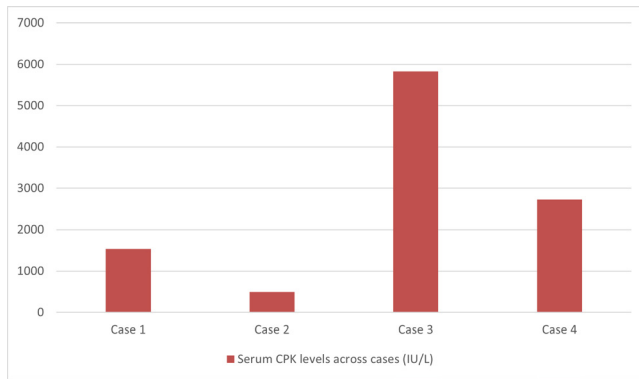
### Case 4

A 46-year-old male from West Bengal presented with a 36-month history of gradually progressive, symmetrical proximal muscle weakness. There were no cutaneous features, dysphagia, respiratory symptoms, or systemic involvement. He had no significant comorbidities or past medical history. Examination showed features of proximal muscle weakness. Initial evaluation revealed elevated CPK (2733 IU/L), positive ANA, and a myopathic EMG pattern.

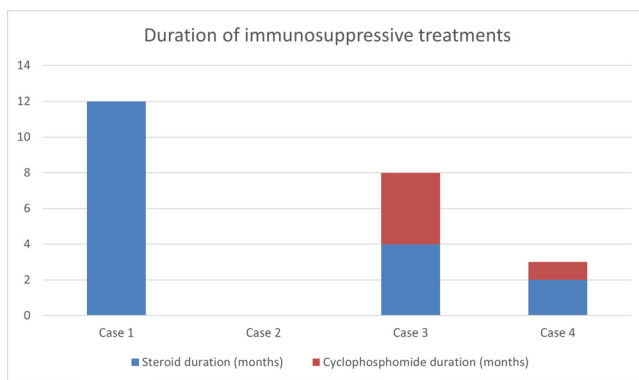
The patient tested positive for Anti-SRP antibodies, again suggestive of Immune-Mediated Necrotizing Myopathy (IMNM). MRI demonstrated muscle edema, while biopsy findings were described as undifferentiated inflammation without necrosis or inclusion bodies. He was treated with oral corticosteroids and a short course of cyclophosphamide (1 month). No IVIg or additional agents were administered. He achieved clinical improvement, with resolution of muscle symptoms. There were no complications or relapse, and the patient remained stable on follow-up.

## 6. Discussion

The four cases describe highlight the heterogeneity of idiopathic Inflammatory Myopathies (IIM), emphasizing the importance of clinicopathological correlation and antibody profiling in diagnosis and prognostication. Case 1 represents Anti Ro52 antibody-positive polymyositis, confirmed by biopsy and responsive to corticosteroids and IVIg, with an excellent outcome despite the absence of adjunctive immunosuppression. Case 2 illustrates the fulminant



**Figure 1.** Serum CPK levels across cases.



**Figure 2.** Duration of immunosuppressive treatments.

nature of anti-SRP-associated immune-Mediated Necrotizing Myopathy (IMNM), which is known for severe weakness, poor steroid responsiveness, and high mortality, underscoring the need for early aggressive immunosuppression and possibly biologic therapy. Case 3 demonstrates classic dermatomyositis with anti-Mi-2 positivity, characteristic biopsy findings, and a favorable prognosis, reflecting the strong therapeutic response typically observed in this subtype. Case 4, also anti-SRP-positive, highlights the variability of IMNM outcomes; the patient achieved remission with corticosteroids and limited cyclophosphamide, suggesting that timely intervention can alter disease trajectory (Figure 2). Collectively, these cases emphasize the need for antibody testing and muscle biopsy whenever feasible to refine diagnosis. The contrasting outcomes between IMNM and dermatomyositis cases highlight the prognostic variability in IIM and the importance of personalized treatment strategies, early

multidisciplinary intervention, and vigilant follow-up to reduce morbidity and mortality.

## 6.1 Limitations

There are a few limitations in our case series. We have not followed up the patients to observe long-term response to treatment. Being a case series, the results cannot be extrapolated to the general population.

## 7. Summary and Conclusion

This case series illustrates the clinical and immunopathological diversity of Idiopathic Inflammatory Myopathies (IIMs). Despite all patients presenting with proximal symmetrical muscle weakness, the underlying diagnoses varied significantly—ranging from polymyositis and dermatomyositis to immune-mediated necrotizing myopathy. This underscores the importance of a systematic diagnostic approach integrating clinical examination, serum CPK levels in the figure 1 and 2, EMG findings, MRI imaging, muscle biopsy, and most crucially, myositis-specific autoantibody profiling (Table 1).

The detection of anti-Mi-2 antibodies in the patient with classic dermatomyositis correlated well with perifascicular atrophy, while anti-SRP positivity, associated with IMNM, was found in two patients and was marked by more severe CPK elevations and variable histology. Anti-Ro52 positivity, though not disease-specific, supported the autoimmune etiology in one case. MRI proved valuable in identifying active muscle inflammation, particularly when biopsy data was lacking.

Therapeutically, early initiation of corticosteroids—supplemented by IVIg or cyclophosphamide in selected cases—resulted in favorable outcomes in all surviving patients. Notably, even traditionally refractory forms like anti-SRP-positive IMNM showed good response when treated promptly. There were no documented relapses or major systemic complications in most cases.

Overall, this series reinforces the role of personalized, antibody-guided diagnosis and management in inflammatory myopathies and highlights the need for multidisciplinary evaluation to optimize patient outcomes.

**Table 1.** Baseline characteristics

Parameters	Case 1	Case 2	Case 3	Case 4
Age/Gender	41/Female	37/Female	27/Male	46/Male
State	West Bengal	Tamil Nadu	Bangladesh	West Bengal
Duration of Symptoms	2 months	24 months	6 months	36 months
Presenting Complaints	Joint pain	Muscle weakness	Muscle weakness	Muscle weakness
Pattern of Weakness	Proximal	Proximal	Proximal	Proximal
Symmetry of Weakness	Symmetrical	Symmetrical	Symmetrical	Symmetrical
CPK(IU/L)	1537	491	5826	2733
ANA	Positive	Negative	Positive	Positive
EMG	Myopathic process	Inflammatory process	Myopathic process	Myopathic process
Autoantibody	Anti Ro 52	Anti SRP	Anti Mi 2	Anti SRP
MRI Findings	Not available	Increased uptake in all muscles	Inflammatory changes	Muscle edema
Muscle Biopsy	Perivascular inflammation	Not available	Perifascicular atrophy	Undifferentiated changes
Diagnosis	Polymyositis	Immune mediated necrotizing myositis	Dermatomyositis	Immune mediated necrotizing myositis
Steroids	Yes (12 months)	Yes	Yes (4 months)	Yes (2 months)
Cyclophosphamide	No	No	Yes (4 months)	Yes (1 month)
IVIg	Yes (12 months)	No	No	No
MTX/AZA/HCQ/ PLEX	Not used	Not used	Not used	Not used
Clinical Response	Good	Good	Good	Good
Complications	None	None	None	None
Relapse/Mortality	No/No	No/Yes (unclear follow up)	No/No	No/No

## 8. References

1. Kulkarni N, Venugopalan A, Saluja M on behalf of doctors and research scientists at center of rheumatic diseases Pune, *et al.*, AB0585 single center experience of clinical profile of inflammatory myositis from India *Annals of the Rheumatic Diseases* 2020; 79:1590 <https://doi.org/10.1136/annrheumdis-2020-eular.5768>
2. Alenzi FM. Myositis Specific Autoantibodies: A Clinical Perspective. *Open Access Rheumatol.* 2020; 14(12):9-14. <https://doi.org/10.2147/OARRR.S231195> PMID:32021502 PMID:PMC6969688.
3. Cruellas MG, Viana VS, Levy-Neto M, Souza FH, Shinjo SK. Myositis-specific and myositis-associated autoantibody profiles and their clinical associations in a large series of patients with polymyositis and dermatomyositis. *Clinics.* 2013; 68(7):909-914. [https://doi.org/10.6061/clinics/2013\(07\)04](https://doi.org/10.6061/clinics/2013(07)04) PMID:23917652.
4. Barsotti S, Lundberg IE. Current treatment for myositis. *Curr Treatm Opt Rheumatol.* 2018; 4(4):299-315. <https://doi.org/10.1007/s40674-018-0106-2> PMID:30613465 PMID:PMC6299051.
5. Torres C, Belmonte R, Carmona L, Gómez-Reino FJ, Galindo M, Ramos B, Cabello A, Carreira PE. Survival, mortality and causes of death in inflammatory myopathies. *Autoimmunity.* 2006; 39(3):205-15. <https://doi.org/10.1080/08916930600622603> PMID:16769654.