



Rare Presentations of Genodermatoses and their Clinical Correlations: A Case Series from Tertiary Care Centre

S. Monica*, P. Merwin, N. Saravanan and C. Vijayabhaskar

Department of DVL, Government Stanley Medical College, Chennai - 600001, Tamil Nadu, India;
monicaramanan@gmail.com, drmerwin@gmail.com, saransudar@gmail.com, buskibuski@gmail.com

Abstract

Genodermatoses are inherited skin disorders with variable clinical and systemic manifestations, usually present from birth or early childhood. Diagnosis relies on clinical evaluation, especially in resource-limited settings. This case series reports four rare presentations. **Aims and Objectives:** To analyse and report the clinical features of five unique cases of Genodermatoses, which include faun tail nevus, intermediate junctional epidermolysis bullosa, verrucous epidermal nevus with scoliosis, and segmental neurofibroma encountered in a tertiary care hospital. **Methodology:** This descriptive case series was conducted in the Department of Dermatology, Stanley Medical College and Hospital, Chennai, between January 2025 and August 2025. Four patients presenting with rare genodermatoses underwent detailed clinical evaluation, including family history, systemic examination, and appropriate investigations. Diagnosis was made mainly by clinical features and aided by other histopathological investigations. **Results:** CASE 1: A 16-year-old female with localized lumbosacral hypertrichosis diagnosed as a Faun tail nevus, a marker of occult spinal dysraphism. CASE 2: A 38-year-old female with unilateral palmar neurofibromas and axillary freckling consistent with segmental neurofibromatosis. CASE 3 and CASE 4: Two siblings (a 14-year-old male and his 9-year-old female sibling) with recurrent blistering, nail dystrophy, enamel hypoplasia, and scarring fulfilling diagnosis criteria for generalized intermediate junctional epidermolysis bullosa. CASE 5: A 15-year-old female with verrucous epidermal nevus, scoliosis, growth retardation, and delayed puberty, suggestive of epidermal nevus syndrome with possible hypogonadotropic hypogonadism. **Conclusion:** This case series underscores the wide spectrum and clinical variability of genodermatoses. Cutaneous manifestations often serve as external markers for underlying systemic or genetic abnormalities. In resource-constrained settings, careful clinical evaluation supplemented by targeted investigations remains essential for diagnosis and management. Early recognition is crucial not only for medical treatment but also for genetic counselling and psychological support.

Keywords: Epidermal Nevus Syndrome, Faun Tail Nevus, Genodermatoses, Junctional Epidermolysis Bullosa, Segmental Neurofibroma, Verrucous Epidermal Nevus, Scoliosis

1. Introduction

Genodermatoses represent a diverse and fascinating group of inherited skin disorders, characterized by various spectra of associated systemic involvement and carrying significant diagnostic, therapeutic, and psychosocial implications. These conditions are rooted in genetic mutations that disrupt the development, structure, or function of skin. The age of onset is mostly

from birth or early childhood and may range from mild pigmentary changes to life-threatening erythroderma and blistering disorders or multisystem syndromes. The skin, being the most visible organ, often serves as the initial window to an underlying genetic anomaly. Advances in molecular genetics and histopathological diagnosis have revolutionized our understanding of genodermatoses, yet many remain misdiagnosed or poorly managed, particularly when presentations are

*Author for correspondence

atypical in nature. But in resource-poor countries, diagnosis of various genodermatoses is mostly clinical. This article presents a case series encompassing four rare cases of genodermatoses and their varied clinical manifestations.

2. Aim and Objectives

This case series aims to analyse and report clinical manifestations of 5 unique cases of genodermatoses, which include faun tail nevus, junctional epidermolysis bullosa, verrucous epidermal nevus with scoliosis, and segmental neurofibroma.

3. Review of Literature

Faun tail nevus: Spinal dysraphism is a collective term for developmental anomalies resulting from defective closure of the caudal neuropore. It encompasses the spectrum of conditions associated with spina bifida. Several cutaneous markers have been described in association with spinal dysraphism, including midline dimples, dermal sinuses, subcutaneous lipomas, port-wine stains, acrochordons, hemangiomas, aplasia cutis, telangiectasia, and other capillary malformations. During embryogenesis, separation of the neuroectoderm from the epithelial ectoderm occurs between the third and fifth week of intrauterine life, beginning along the posterior midline¹. Any interruption or incomplete cleavage during this period may result in defects involving the skin, vertebrae, spinal cord, or central nervous system. Congenital hypertrichosis over the lumbosacral region is considered a significant cutaneous marker of underlying spinal dysraphism. Midline cutaneous lesions frequently serve as external markers of such defects, often enabling early diagnosis².

Common presentations include lumbosacral lipoma, localized hypertrichosis, abnormal gluteal clefts or dimples, and vascular malformations, including haemangiomas over or near the midline³. Hypertrichosis appearing as a lozenge-shaped lumbosacral patch, referred to as a Faun tail nevus or Silky down, is a well-recognized indicator of underlying spinal anomalies. The faun tail is a wide patch of coarse terminal hair, which is several inches long and commonly associated with spinal dysraphism.

Identifying a localized patch of terminal hair in the lumbosacral region is a crucial clinical feature, as it can be the sole external sign of serious spinal anomalies requiring early neurosurgical intervention⁴.

3.1 Segmental Neurofibroma

Neurofibroma is a set of inherited disorders of benign nerve sheath tumors, which are originally designated as neurofibromatosis type 1, neurofibromatosis type 2, and schwannomas. According to Riccardi's classification, neurofibromatosis is classified into eight types. Segmental neurofibromas are type V neurofibromatosis which presents as either multiple café-au-lait macules or neurofibromas in a segmental distribution with no crossing of the midline, no family history, and no systemic involvement. Segmental neurofibromas are further classified as true segmental localized with deep involvement, hereditary, and bilateral. It is a rare form of neurofibromatosis, with an estimated prevalence of 0.014-0.02%. It is characterized by lesions confined to a limited body segment, typically not crossing the midline and without systemic features. The vast majority of patients (93%) have no family history of neurofibromatosis.

3.2 Pathogenesis

Segmental neurofibroma generally arises due to a post-zygotic somatic mutation in the NF1 gene located on chromosome 17q11.21, leading to a mosaic distribution of the mutation. Another mechanism is Loss of Heterozygosity (LOH), in which the abnormal allele is present in all cells, but the second normal allele is lost in the affected segment.

- In LOH-associated cases, additional features such as Lisch nodules or axillary freckling may be present, and the genetic transmission risk is similar to generalized NF1 (50%).
- In post-zygotic mosaicism, systemic involvement is uncommon; however, gonadal mosaicism may occur, particularly when more than one segment is involved. This increases the risk of having children with generalized NF1, even if the parent appears to have localized disease.

Riccardi's classification originally designated SNF as Type V NF, which was further subdivided into:

- True segmental-localized, dermatomal involvement with or without deep tissue extension.
- Hereditary segmental-similar distribution but with family history.
- Bilateral segmental: involvement on both sides but in a segmental pattern.

Lesions are usually unilateral, with the most common dermatomal distribution being cervical, followed by the thoracic, lumbar, and sacral regions. Disease progression is similar to generalized NF1 pigmentary changes, often appearing in childhood, whereas neurofibromas develop in adulthood.

The specific investigation modalities for neurofibromatosis include

- Biopsy: Neurofibroma shows small dermal tumours that are relatively circumscribed and non-encapsulated. Thin spindle cells with elongated, wavy collagenous strands, either closely spaced (homogenous pattern) or loosely spaced in a clear matrix (loose pattern) or both intermixed in a single lesion, can be seen.
- Immunohistochemistry: S100, Sox10, CD34, EMA, and neurofilament protein are positive. In schwannoma-S100, Sox 10 and GFAP are alone positive.
- MRI- It is the first line of imaging modality for distinguishing neurofibroma from common nodules. The “target sign” findings describe the peripheral enhancing rim and hypointense central regions on T2-weighted MRI. The common differential diagnoses are ganglion cysts, epidermal cysts, fibromas of the tendon sheath, and lipomas, which can all be differentiated by MRI.
- CT- As MRI can't differentiate between nerve sheath tumours like schwannomas and neurofibromas; other imaging modalities like CT can be helpful to narrow down the diagnosis. But biopsy and immunohistochemistry are the gold standard.

Junctional Epidermolysis Bullosa: Inherited epidermolysis bullosa is a group of genetic diseases characterized by skin fragility and caused by mutation in the genes encoding different proteins with roles in cell adhesion.

Junctional epidermolysis bullosa is a subtype of EB in which dermal-epidermal adhesion is reduced

due to deficiencies in one of the proteins laminin-332, type XVII collagen, integrin alpha6beta4, or integrin alpha3. This type of EB is all of the autosomal recessive group of inheritance, with varied clinical manifestations. Depending upon the type of junctional EB, presentation varies from discrete erosions and blistering on extremities, nail dystrophy, and excessive crusting and scarring on the trunk resulting in squamous cell carcinoma. Morphology-based clues, like neonatal blistering and mucosal involvement, enable bedside recognition before genetic confirmation as the prime step in resource-poor settings⁵.

Recently a very reliable and important mode of diagnosis for genetic blistering disorder was published by Yenamandra VK, Moss C *et al.*, where they developed a clinical diagnostic matrix for inherited epidermolysis bullosa in the British Journal of Dermatology. If we apply the clinical diagnostic matrix we can differentiate between Epidermolysis Bullosa Simplex (EBS), Junctional Epidermolysis Bullosa (JEB) and Dystrophic Epidermolysis Bullosa (DEB).

This clinical diagnostic matrix includes:

1. Distribution of the skin lesions (generalized/herpetiform)—Generalized.
2. Excessive granulation tissue
3. Scarring
4. Milia
5. Nail dystrophy
6. Nail avulsion
7. Mucosal erosion
8. Eye involvement
9. Hoarseness of voice
10. Microstomia
11. Poor dental enamel pitting with discoloration
12. Keratoderma
13. Chronic non-healing wound
14. Syndactyly
15. Scarring alopecia
16. Poikiloderma
17. Relative growth failure
18. Survival from 2 years ago to present
19. Parents affected.

The specific investigations for junctional epidermolysis bullosa include:

I) Immunofluorescence mapping: We check for loss or absence of laminin 332 or type XVII collagen in intermediate junctional epidermolysis bullosa.

Antibodies used:

- Laminin 332 (LAMA3, LAMB3, LAMC2)- absent or reduced in junctional bullosa
- Type XVII collagen (BP180) (COL17A1)- reduced in JEB
- TYPE VII collagen (COL7A1)- reduced or absent in dystrophic e bullosa.
- Keratin 14 & keratin 5- reduced in EB simplex
- Integrin a6b4 (ITGA6, ITGB4)- absent in JEB with pyloric atresia.

II) Transmission Electron Microscopy (TEM): It visualizes lamina lucida cleavage and reduced or abnormal hemidesmosomes in JEB and loss of anchoring fibrils in DEB.

III) Next-Generation Sequencing (NGS) Gene Panel: It's the definitive diagnosis and inheritance confirmation. EB-specific multigene panels cover KRT5, KRT14, LAMA3, LAMB3, LAMC2, COL17A1, ITGA6, ITGB4, and COL7A1.

IV) Histopathology: Not diagnostic, as we see only a sub-epidermal bulla, as the level of split is in lamina lucida. A shave biopsy is preferred, and a sufficient amount of dermis allows examination of the entire dermal-epidermal junction.

Treatment:

Generally, the prognosis and morbidity are better in the case of intermediate junctional epidermolysis bullosa when compared to other types.

- The major challenge in management is chronic disability and repeated trauma-induced blisters. The patient must be advised to avoid mechanical trauma.
- Oral and dental treatment includes application of reconstructive measures to permanent teeth, crown placement, and tooth implantation.
- Adequate maintenance of nutrition and a balanced diet for growing children, as deficiencies of vitamins and trace elements are frequent. (zinc, iron, selenium).
- Virtually all patients have bony changes, mainly osteoporosis due to poor nutrition; vitamin D deficiency is reported. Regular DEXA scans are routine management.

- Recently autologous split-thickness skin grafting has shown short- to longer-term benefit in the treatment of chronic ulcers and erosions.
- Gene therapy, the most successful modality of treatment done in 2017 with *ex vivo* keratinocyte genes using the LAMB3 transgene, was used for 80% correction with an intermediate form of junctional EB.
- In junctional EB, it is common to observe small patches of skin that do not blister in pale-skinned individuals. This phenomenon is called revertant mosaicism.
- Early clinical suspicion is vital, since supportive wound care must begin immediately, even before lab confirmation⁶.
- Correct clinical diagnosis of the subtype is foremost essential, as it guides appropriate investigations, such as which immunofluorescence or genetic tests to do⁷.
- Even with advanced gene therapy, initial clinical diagnosis remains the gateway to triaging patients for molecular therapies⁸.

3.3 Verrucous Epidermal Nevus with Scoliosis

The term “epidermal nevus syndrome” is a broad term including several more well-defined neurocutaneous syndromes and skeletal anomalies associated with epidermal nevi. In this group of disorders, Verrucous Epidermal Nevus Syndrome (VENS) with scoliosis and potentially other developmental anomalies is associated with PIK3CA mutations. The PIK3CA gene plays a crucial role in cell growth and development, and mutation in this gene leads to various overgrowth syndromes, including VENS. Recognizing segmental distribution along Blaschko's lines is the cornerstone before considering molecular confirmation⁹. Epidermal Nevus Syndrome (ENS) denotes the presence of verrucous epidermal nevus in association with various developmental abnormalities of the skin, eyes, nervous, skeletal, cardiovascular, and urogenital systems. Prevalence of verrucose epidermal nevus is seen in 1:1000 live births. In this patient there was a verrucose epidermal nevus with an x-ray showing mild scoliosis at the T11 to L1 region. It's mainly due to post-zygotic mosaicism in ENS, which affects both ectodermal (skin) and mesodermal (bone and

endocrine glands) derivatives. Mutations in the PI3K-AKT-mTOR pathway genes (PIK3CA, FGFR3, HRAS, and KRAS) could disrupt growth regulation, skeletal morphogenesis, and gonadal development.

3.4 Investigation

The keratinocytic (verrucous) epidermal nevus syndrome investigation includes

1. Routine haematological and biochemical investigation.
2. X-ray of the spine-thoracolumbar scoliosis to look for vertebral anomalies.
3. Hormonal profile for LH, FSH, oestradiol, prolactin, and TSH
4. USG abdomen
5. MRI spine
6. Biopsy of verrucose epidermal nevus-Marked hyperkeratosis, orthokeratosis, focal parakeratosis, acanthosis, papillomatosis, basal cell hyperpigmentation, and mild perivascular lymphocytic infiltrates.

3.5 Management

- Verrucose epidermal nevus can be ablated by electrosurgery or by CO₂ laser. Shave excision with phenol application can be done.
- A thoracolumbosacral orthosis brace will prevent progression of scoliosis. Physiotherapy focusing on core strengthening and posture.
- Endocrinology intervention for confirmation and management of hypogonadotropic hypogonadism.
- If possible, targeted sequencing for PIK3CA/FGFR3 mutation can be done.

4. Material and Methods

This case series includes 5 patients presenting with rare manifestations of genodermatoses, which include faun tail nevus, junctional epidermal nevus, verrucose epidermal nevus syndrome, and segmental neurofibroma, who visited the Department of Dermatology, Stanley Medical College, Chennai, between January 2025 and August 2025. All enrolled patients underwent a detailed clinical assessment, including a history of the lesion's evolution, a detailed family history, detailed clinical examinations, and appropriate investigations, including X-rays, biopsy, and MRI findings. To confirm the diagnosis, an incisional

skin biopsy was performed for verrucose epidermal nevus with scoliosis, junctional epidermolysis bullosa, and segmental neurofibroma. All the patients were evaluated. Interventions and data recordings were performed in accordance with standardized clinical protocol and with informed consent.

5. Results (Including Observations)

CASE 1: A 16-year-old female presented with excessive hair growth over the lumbosacral (LS) region since birth. Her parents noticed the hairy patch with coarse hairs over her lumbosacral region since birth. There was no history of back pain, urinary incontinence, paraesthesia, lower limb weakness, or gait disturbances. The child has never undergone medical evaluation. She is the second child born to non-consanguineous parents, with a healthy older sibling. Pregnancy, delivery, and the neonatal period were uneventful. She was born at term via spontaneous vaginal delivery, and her growth and developmental milestones were age-appropriate. There is no family history of similar lesions or other congenital anomalies (Figure 1).

On physical examination, a well-circumscribed 15x20 cm patch of hypertrichosis was present in the midline LS region. The patch was covered with coarse, dark terminal hairs of varying length, with the underlying skin appearing normal in texture and pigmentation. No underlying swelling, sinus, dimpling, or discoloration was noted. Systemic examination was unremarkable.

Neurological examination revealed normal muscle tone, bulk, and grade 5 power in all muscle groups of

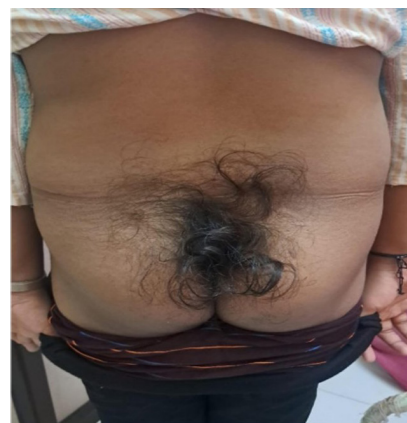

Figure 1. Faun tail nevus.

the lower limbs. Deep tendon reflexes were symmetrical and within normal limits. On examination sensation was intact. Her gait was normal, and there was no evidence of foot deformity or limb length discrepancy. Based on the clinical findings, a diagnosis of faun tail nevus was made, which was recognized as a cutaneous marker of underlying spinal dysraphism. Given the risk of occult spinal anomalies such as tethered cord or spina bifida occulta, further radiological evaluation was advised to rule out any associated intraspinal abnormality.

CASE 2: A 38-year-old female born out of a non-consanguineous marriage presented with multiple skin-colored, asymptomatic, fixed, raised lesions present over the left palm for 2 years and no other history suggestive of cutaneous symptoms of neurofibroma and with no other underlying systemic diseases. She denied a history of trauma, pain in the lesions, and similar lesions in the siblings or other family members (Figure 2).

On physical examination, multiple skin-colored nodules, 4 in number, ranging in size from 3x2 cm to 2x2 cm, are present over the base of the palmar aspect of the 4th phalanx (ring finger) of the left hand. A single skin-colored nodule is present over the palmar aspect of the left hand, 3.5 cm proximal to the 3rd interdigital space, of size 3x2 cm. A few discrete, hyperpigmented macules measuring 1-2 cm were seen clustered within

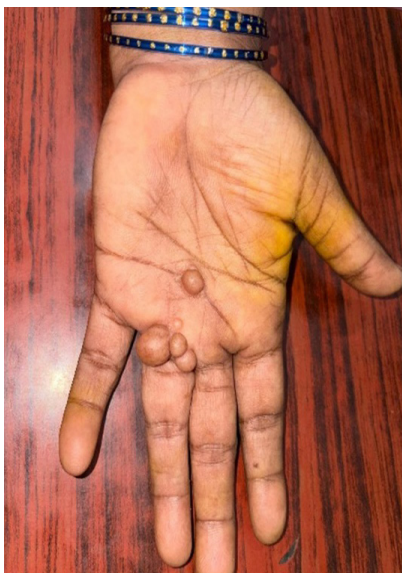

Figure 2. Segmental neurofibroma.

the left axillary fold. Minimal axillary freckling was noted during examination.

On palpation, the nodules were non-tender, soft to rubbery, with intact overlying dermatoglyphics.

Haematological investigations were within normal limits. The excision biopsy from the nodule on the palm showed well-demarcated non-encapsulated nodules in the reticular dermis consisting of numerous cells with spindle-shaped tapering nuclei on haematoxylin and eosin stain consistent with the diagnosis of neurofibroma.

Other system examinations: The patient was normotensive, and ultrasonography of the abdomen and pelvis was normal. The auditory examination and ophthalmic examination, including slit-lamp and fundoscopy, were normal.

5.1 Interpretation

Classification: According to Revised Diagnostic Criteria for Mosaic NF1 (2021 Consensus):

- Criterion 1- Pathogenic variants in <50% of cells=1 other NF1 feature. No genetic testing done—so this criterion is not applicable.
- Criterion 2- same pathogenic variants in > 2 independent affected tissues, absent in unaffected tissue.
- No molecular testing is done; hence, this criterion is not applicable.
- Criterion 3- Segmental pattern of skin findings + another NF1 diagnosis criterion. There is segmental distribution of palmar neurofibromas in one dermatome, with additional NF1 diagnostic criterion which is, axillary freckling on the same left axillary fold. The freckling is unilateral and ipsilateral to segmental neurofibroma, which is consistent with gonadal mosaicism.
- Criterion 4- one NF1+affected offspring. Not applicable, as there is no affected offspring. As presence of any one criteria is sufficient and a diagnosis of Segmental NF-1 is made.

The presence of pigmentary change along with neurofibroma increases the suspicion that NF1 due to gonadal mosaicism may be the reason for this patient to present as segmental neurofibroma. Thus, after analyzing the clinical features and histopathological

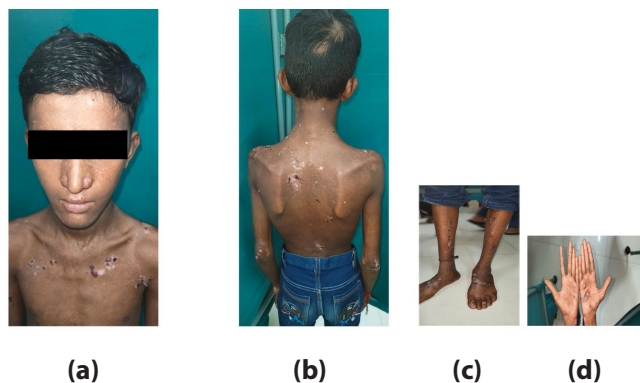


Figure 3. Generalized intermediate junctional epidermolysis bullosa.

appearance, a final diagnosis of isolated palmar neurofibroma was concluded.

CASE 3: A 14-year-old boy, the first child born to healthy non-consanguineous parents, presented with a history of recurrent blisters for 2 months of age. Lesions were provoked even by minor trauma and healed with scarring (Figure 3a, 3b, 3c, 3d).

On examination: The growth and development were appropriate for age.

A few tense bullae of size 3x3 cm to 2x1 cm are present over the bilateral palms, trunk, back, and lower limbs. Multiple atrophic scars over the healed sites and multiple erosions over healing lesions are present over the back, trunk, bilateral upper limbs, and bilateral lower limbs.

Nail dystrophy affecting all fingernails and toenails. Patchy scarring alopecia is present over the scalp.

Enamel hypoplasia with pitting and discoloration of teeth was present.

There were no oral, ocular, or genital mucosal erosions or blisters. No syndactyly or mitten deformity noted.

CASE 4: A 9-year-old girl, the second child born to healthy non-consanguineous parents, who is the younger sibling of CASE 3, presented with a history of recurrent blisters for 1 month of age. Lesions were provoked even by minor trauma and healed with scarring. This child also has clinical features similar to her older sibling.

The parents are clinically normal with no history of similar skin lesions in the family. Both siblings were born out of full-term normal vaginal delivery without

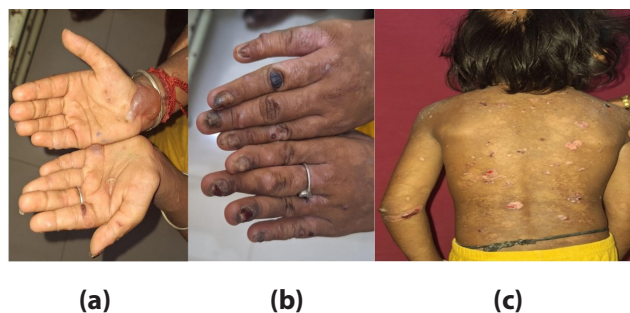


Figure 4. Generalized intermediate junctional epidermolysis bullosa.

any perinatal complications. This pattern is suggestive of autosomal recessive inheritance (Figure 4a, 4b, 4c).

Investigations: Both biochemical and haematological investigations were within normal limits for both siblings.

On biopsy: A sub-epidermal bulla plane of cleavage closer to the basal keratinocyte layer, without any inflammatory infiltrates within the blister cavity, was present in both the siblings.

More specific investigations like immunofluorescence antigen mapping (IFM), the gold standard, Transmission Electron Microscopy (TEM), and Next-Generation Sequencing (NGS) panels were not done due to lack of resources.

Recently a very reliable and important mode of diagnosis for genetic blistering disorder was published by Yenamandra VK, Moss *C et al.*, where they developed a clinical diagnostic matrix for inherited epidermolysis bullosa in the British Journal of Dermatology. If we apply the clinical diagnostic matrix,

1. Distribution of the skin lesions (generalized/herpetiform)- Generalized.
2. Scarring- present
3. Nail dystrophy- present
4. Poor dental enamel pitting with discoloration- present
5. Scarring alopecia- present
6. Survival from 2 years age, to present
7. Parents affected- not affected.

As 7 out of 19 criteria were fulfilled, a diagnosis of generalized intermediate epidermolysis bullosa was made for both the siblings, as same clinical features were present for both the siblings.

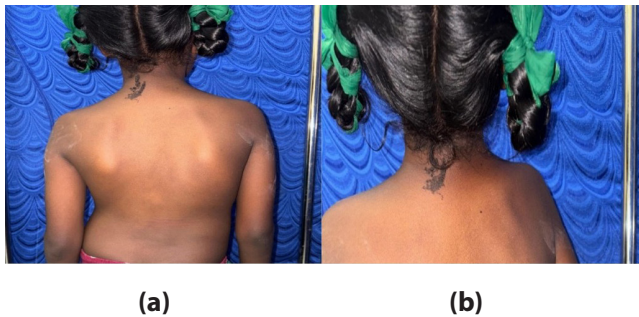


Figure 5. Verrucous epidermal nevus with scoliosis

CASE 5: A case of epidermal nevus syndrome with verrucose epidermal nevus.

A 15-year-old female child whose parents are normal, born out of a non-consanguineous marriage, by normal vaginal delivery. The patient has growth retardation at present. The patient presented with complaints of dark-colored raised linear lesions over the back of the neck area since birth, which have progressively thickened over time. The patient has not attained menarche. The patient has no history of seizures, developmental delay, visual disturbances, or hearing impairment. No family history of similar lesions at present (Figure 5a, 5b).

5.2 On examination

General examination:

- Height: 138 cm (<3rd percentile for age, WHO growth charts)
 - Weight: 33 kg (<3rd percentile)
 - BMI: 17.3 kg/m²
 - Arm span: 138 cm
 - Blood pressure: 100/76 mm Hg Secondary sexual characteristics:
 - Breast development: Tanner stage-II
 - Pubic hair: Tanner stage – I
 - Axillary hair: Nil
 - No signs suggestive of hyperandrogenism
- Dermatological examination:

Multiple well-defined, hyperpigmented, verrucous plaques arranged in a linear manner, ranging in size from 0.5x0.5 cm to 3x2 cm, extending from the left retro auricular region to the nape of the neck. Lesions were non-tender and non-blanchable.

Mild lumbar scoliosis is present on visible spinal curvature on forward bending at the T11-L1 level. No

Table 1. Summary of various features of genodermatoses.

Case	Age/Sex	Clinical Presentation	Investigation	Diagnosis	Comments
CASE 1	16/F	Lumbosacral hypertrichosis since birth no clinical neurological deficit	Clinical examination, Advised MRI spine	Faun tail nevus	It's a cutaneous marker without neurological symptoms clinically.
CASE 2	38/F	Multiple palmar nodules (3-4cm) Ipsilateral axillary freckling no systemic involvement.	Biopsy : Non-encapsulated dermal tumor with spindle cells.	Segmental neurofibromatosis (Mosaic NF 1)	Localized neurofibroma in the palms with ipsilateral axillary freckling
CASE 3	14/M	Both patients were siblings with almost same clinical manifestation of recurrent bullae since infancy, scarring alopecia, enamel hypoplasia and nail dystrophy	BIOPSY : Sub-epidermal bulla	Generalized intermediate Junctional epidermolysis bullosa	Autosomal recessive inheritance, both siblings affected, diagnosis based on clinical matrix
CASE 4	9/F	Both patients were siblings with almost same clinical manifestation of recurrent bullae since infancy, scarring alopecia, enamel hypoplasia and nail dystrophy.	BIOPSY : Sub-epidermal bulla	Generalized intermediate Junctional epidermolysis bullosa	Autosomal recessive inheritance, both siblings affected, diagnosis based on clinical matrix
CASE 5	15/F	Linear verrucous plaques over neck since birth, growth retardation, scoliosis and delayed puberty	BIOPSY : (Keratinocytic nevus), X-ray (scoliosis) and growth evaluation	Epidermal nevus syndrome with scoliosis	Unique association of epidermal nevus with skeletal deformity and growth / puberty delay.

limb length discrepancy, joint swelling, or restricted limb movements.

A clinical diagnosis of keratinocytic epidermal nevus syndrome with lumbar scoliosis with probable hypogonadotropic hypogonadism and growth retardation is made.

Thus, as seen in Table 1, we analyzed and reported the clinical features of five unique cases of Genodermatoses, which included faun tail nevus, intermediate junctional epidermolysis bullosa, verrucous epidermal nevus with scoliosis, and segmental neurofibroma.

6. Discussion

CASE 1: Faun Tail Nevus: Our patient presented with localized hypertrichosis in the lumbosacral region and was advised to get an MRI of the spine to rule out spina bifida with diastematomyelia. In occult forms of spinal dysraphism, surgical intervention is typically indicated only in the presence of tethered cord, spinal instability, or other neurological compromise.

The patient's primary concern was with a request for removal of the excessive hair. So, the diode laser hair reduction option was discussed with the patient. This case is noteworthy for the rarity of the spinal anomalies presenting without clinical features of neurological deficits. Thus, clinical suspicion based on cutaneous markers remains the most important modality, which is then confirmed by MRI¹⁰.

CASE 2: Our patient, 38-year-old female presented with multiple skin-coloured, asymptomatic, fixed, raised lesions present over the left palm for 2 years and with few discrete, hyperpigmented macules measuring 1-2 cm were seen clustered within the left axillary fold. No other history suggestive of cutaneous symptoms of neurofibroma and with no other underlying systemic diseases. Based on Revised Diagnostic Criteria For Mosaic NF1 (2021 Consensus), as there is segmental distribution of palmar neurofibromas in one dermatome, with additional NF1 diagnostic criterion which is, axillary freckling on the same left axillary fold (ipsilateral), Criterion 3 was fulfilled and a diagnosis of Segmental NF1 was made.

Management: BIOPSY: For this patient, a biopsy was taken, and HPE features of neurofibroma was confirmed

.Biopsy showed a small dermal tumour, relatively circumscribed and non-encapsulated. Thin spindle cells with elongated, wavy nuclei are regularly spaced among thin, wavy collagenous strands with a closely spaced homogenous pattern. Immunohistochemistry: Neurofibromatosis-specific markers like S100, Sox10, CD34, EMA, and neurofilament protein were not done.

1. Imaging modalities like T2-weighted MRI and CT were suggested.

Treatment: Surgery is indicated for lesions greater than 4 cm if suspected neurofibroma causes pain, sudden growth in size, and limitation of movements. This patient was referred to plastic surgery for excision of the neurofibromas, as the patient wanted a complete removal of the NF lesions even though the chance of recurrence was explained.

CASE 3 and CASE 4

CASE 3: A 14-year-old boy, the first child born to healthy non-consanguineous parents, presented with a history of recurrent blisters since 2 months of age. Lesions were provoked even by minor trauma and healed with scarring.

CASE 4: A 9-year-old girl, the second child born to healthy non-consanguineous parents, who is the younger sibling of CASE 3, presented with a history of recurrent blisters for 1 month of age. Lesions were provoked even by minor trauma and healed with scarring. This child also has clinical features similar to her older sibling.

The diagnosis of generalized intermediate junctional epidermolysis bullosa was mainly done based on Yenamandra VK, Moss C *et al*¹¹.

- Onset in Infancy: Typical characteristics of inherited EB.
- Generalized tense bullae with atrophic scarring
- Nail dystrophy—Intermediate JEB involves almost all the nails.
- Enamel hypoplasia—highly suggestive of intermediate JEB due to defective basement membrane anchoring at the ameloblast interface.
- Scarring alopecia secondary to scalp blistering
- Two affected siblings with unaffected parents are compatible with autosomal recessive inheritance.
- Survival from 2 years age, to present

As 7 out of 19 criteria were fulfilled by both the siblings, a diagnosis of Intermediate junctional Epidermolysis bullosa was made. The patient usually survives to adulthood. There is a gradual lessening in the severity of the disease with age.

Investigations: Biopsy: A shave biopsy was done for both siblings. It showed a sub-epidermal bulla; the level of split was in the lamina lucida.

1. Other specific investigation modalities like immunofluorescence mapping, transmission electron microscopy, and Next-Generation Sequencing (NGS) gene panels were suggested.

Treatment: Generally, the prognosis and morbidity are better in the case of intermediate junctional epidermolysis bullosa when compared to other types.

- Siblings were advised to avoid mechanical trauma like wearing socks, cotton clothing, and turning the garments inside out to prevent seams from rubbing.
- Shoes should be soft, wide, and padded.
- Avoidance of tight-fitting clothing with zippers.
- Bedding with soft cotton sheets and pillowcases.
- Encouraging safe activities that minimize trauma.
- Usage of non-adhesive, paraffin-impregnated dressings like Vaseline gauze.

Adequate maintenance of nutrition and a balanced diet for the siblings was suggested, as deficiencies of vitamins and trace elements are frequent (zinc, iron, selenium). The parents were advised about regular follow-up for the siblings, for monitoring nutritional deficiencies and correction of dental abnormalities. A regular DEXA scan was advised as a part of routine management to look for osteoporosis. Genetic counselling was done with the parents.

CASE 5: A 15-year-old female patient presented with complaints of dark-colored raised linear lesions over the back of the neck area since birth, which have progressively thickened over time. The patient has not attained menarche. The patient has no history of seizures, developmental delay, visual disturbances, or hearing impairment. Mild lumbar scoliosis is present on visible spinal curvature on forward bending at the T11-L1 level. A clinical diagnosis

of keratinocytic epidermal nevus syndrome with lumbar scoliosis with probable hypogonadotropic hypogonadism and growth retardation is made.

Investigation: The keratinocytic (verrucous) epidermal nevus syndrome investigation includes

- Routine haematological and biochemical investigations were normal.
- An X-ray of the spine with thoracolumbar scoliosis showed a Cobb angle of 28 with no vertebral anomalies.
- A hormonal profile for LH, FSH, oestradiol, prolactin, and TSH was suggested.
- USG abdomen and MRI spine were suggested.
- A biopsy of the verrucous epidermal nevus was done, showing marked hyperkeratosis, orthokeratosis, focal parakeratosis, acanthosis, papillomatosis, basal cell hyperpigmentation, and mild perivascular lymphocytic infiltrates.

Management

- Verrucous epidermal nevus excision by electrosurgery was planned for this patient.
- An orthopaedic opinion for the management of scoliosis and physiotherapy was suggested.
- Endocrinology and obstetric opinion for delayed puberty was suggested to the patient.
- Targeted sequencing for PIK3CA/FGFR3 mutation was not done.

7. Summary and Conclusion

In this case series, the clinical features of five unique cases of Genodermatoses, which include faun tail nevus, two cases of intermediate junctional epidermolysis bullosa, verrucous epidermal nevus with scoliosis, and segmental neurofibroma were analysed in detail, as seen in Pie Chart 1.

Pie Chart 1

Faun tail nevus is a very rare neurocutaneous marker of spinal dysraphism. Managing the faun tail nevi must be undertaken to reduce their psychological impact on the affected. IPL laser or diode laser options can be tried for long-lasting effect in permanent hair reduction.

- The case of segmental neurofibroma can be confirmed as it fulfilled the Revised Diagnostic Criteria For Mosaic NF1 (2021 Consensus), even without the need of biopsy. The signs of skin manifestations remain the diagnostic anchor, even in the genomic era¹².
- We reported two siblings with clinical features consistent with generalized intermediate junctional epidermolysis bullosa. The presence of atrophic scars, nail dystrophy, alopecia, and enamel hypoplasia in the absence of mucosal involvement was seen in both the siblings. Only conservative management can be done at present for the patients. Genetic counselling is essential for the parents.
- We presented a rare case of (keratinocytic) verrucous epidermal nevus syndrome with thoracolumbar scoliosis, with probable hypogonadotrophic hypogonadism and growth retardation. This case underlines the importance of comprehensive systemic evaluation in patients with VEN, especially when associated with scoliosis and pubertal delay.

In conclusion, detailed study of rare genodermatoses and their varied clinical presentation is crucial for timely diagnosis and holistic care, especially in resource-constrained health systems.

8. References

1. Faun tail nevus: A series of 15 cases and their management with Intense Pulse Light by Sandeep Arora, Gulhima Arora *et al.*
2. Faun tail nevus- a case report. Arora S, Rawat S, Banerjee A *et al.* Med J Armed forces India.
3. Antony F.C, Holden C. A Diffuse hypertrichosis and faun-tail nevus as cutaneous markers of spinal dysraphism. Clin Exp Dermatol.
4. Khanna M, Dhamija R, Bhat V, Sharma A. Faun tail nevus: A marker of spinal dysraphism. Indian J Dermatol. 2009; 75(6):630-631.
5. DermNet NZ. Junctional epidermolysis bullosa. Update; 2023.
6. Natsuga K. Epidermolysis bullosa: From clinical diagnosis to therapy. Clin Cosmet Investig Dermatol. 2015; 8:275-283.
7. Fine JD, Brunckner-Tuderman L, Eady RA, *et al.* Inherited epidermolysis bullosa: Updated classification and diagnosis. J AM Acad Dermatol. 2014; 70(6):1103-1126. <https://doi.org/10.1016/j.jaad.2014.01.903> PMID:24690439.
8. Vahidnezhad H, Youssefian L, Uitto J. Genomics and precision medicine in epidermolysis bullosa: Current status and perspective. Exp Dermatol. 2021; 30(10):1441-1456.
9. Happle R. Epidermal nevus syndrome; Mosaic RASopathies and beyond. Am J Med Genet. 2016; 172(2):171-182.
10. Ergun T, Lakadamyali H. MRI findings of spinal dysraphism in patients with cutaneous stigmata. Diagn Interv Radiol. 200; 16(2):125-132.
11. Yenamandra VK, Moss C, Sreenivas V, Khan M, Sivasubbu S *et al.* Development of a clinical diagnostic matrix for characterizing inherited epidermolysis bullosa. British Journal of Dermatology. 2017; 176(6). <https://doi.org/10.1111/bjd.15221> PMID:27925151.
12. Ferner RE, Huson SM, Thomas N, *et al.* Guidelines for the diagnosis and management of individual with neurofibromatosis. J Med Genet. 2007; 44(2):81-88. <https://doi.org/10.1136/jmg.2006.045906> PMID:17105749 PMCID: PMC2598063.